

TRICKS MRA

¹Dr. Asha M.L, ^{2*}Dr. Aprajita Dua, ³Dr. Chaitanya Reddy, ⁴Dr. Lekshmy.J, ⁵Dr. Basetty Neelakantam Rajarathnam and ⁶Dr. Mahesh Kumar H.M

¹Department of Oral Medicine and Radiology, Dr. Syamala Reddy Dental College, Hospital and Research Centre, Bangalore; MDS.

²Department of Oral Medicine and Radiology, Dr. Syamala Reddy Dental College, Hospital and Research Centre, #111/1, SGR College Main Road, Munnekolala, Marathahalli (Post), Bangalore- 560037; (MDS).

³Department of Public Health Dentistry, Dr. Syamala Reddy Dental College, Hospital and Research Centre, Bangalore; MDS.

⁴Department of Oral Medicine and Radiology, Dr. Syamala Reddy Dental College, Hospital and Research Centre, Bangalore; MDS.

⁵Department of Oral Medicine and Radiology, Dr. Syamala Reddy Dental College, Hospital and Research Centre, Bangalore; MDS.

⁶Department of Oral Medicine and Radiology, Dr. Syamala Reddy Dental College, Hospital and Research Centre, Bangalore; MDS.

Article Received on
10 August 2016,

Revised on 30 August 2016,
Accepted on 19 Sept. 2016

DOI: 10.20959/wjpr201610-7138

*Corresponding Author

Dr. Aprajita Dua

Department of Oral
Medicine and Radiology,
Dr. Syamala Reddy Dental
College, Hospital and
Research Centre, #111/1,
SGR College Main Road,
Munnekolala, Marathahalli
(Post), Bangalore- 560037;
(MDS).

ABSTRACT

Head-neck vascular anomalies (HNVA) are congenital aberrancies of vascular development; clinical appearance of which depends on their depth and phase of growth. The diagnosis of haemangiomas or vascular malformations is most often a clinical one; imaging plays a pivotal role in the diagnosis of more challenging cases and in planning the therapeutic approach that may consist of pharmacological embolization, sclerotherapy or surgery. Doppler ultrasonography is the first imaging modality used to characterize maxillofacial superficial lesions and their haemodynamic conditions; but Doppler ultrasonography is not able to depict the real extension and, most importantly, the vascular anatomy of complex HNVA. Contrast CT may provide further information by identifying calcifications and in demonstrating involvement of major vessels after contrast injection, but they use considerable X-ray dosages (avoidable especially in young

patients). MRI and MR angiography (MRA) represent the best diagnostic tools to demonstrate, respectively, soft-tissue components and relationships with nearby structures and to provide useful information on HNVA feeding vessels. Time-resolved imaging of contrast kinetics (TRICKS) is a recently introduced keyhole technique that improves

temporal resolution with respect to contrast-enhanced MRA technique; by this, one can obtain dynamic images during the arterial, capillary and venous phases. This review provides an insight into this technique.

INTRODUCTION

Head-neck vascular anomalies (HNVA) are congenital aberrancies of vascular development; their clinical appearance depends on their depth and phase of growth.^[1]

Imaging plays a pivotal role in the diagnosis of more challenging cases and in planning the therapeutic approach.^[2]

Magnetic resonance angiography (MRA) is an application of magnetic resonance imaging (MRI) that provides visualization of blood flow, as well as images of normal and diseased blood vessels.^[3]

Arteriovenous malformations (AVMs) are congenital vascular malformations that result from defects involving the vessels of both arterial and venous origins, resulting in a meshwork of primitive reticular networks of dysplastic minute vessels termed “nidus”

The overall prevalence of vascular malformations is estimated to be 1.5% in population They require treatment mainly because: Tendency to enlarge, pain, deformity, arterial steal phenomenon, ulceration, haemorrhage, impaired function.^[4-6]

Need for imaging Head and Neck Vascular Anomalies

Depending on the appearance of head and neck vascular anomaly on the magnetic resonance angiographic image:

1. Small nidus and single arterial Feeder of arteriovenous malformation: Sclerotherapy
2. Large nidus and single arterial feeder of arteriovenous malformations :Embolization
3. Large nidus and multiple arterial feeders of arteriovenous malformations: Sclerotherapy and embolization.^[8]

Previous Imaging Modalities

Digital Subtraction Angiography

permits visualization of the arterial feeders, nidus, and venous drainage of AVMs of head and neck with high spatial and temporal resolution.

Unfortunately, DSA is relatively expensive, time consuming, with risk of vascular injury and exposure to ionizing radiation.^[6,7]

Computed Tomography Angiography

Improved temporal resolution as well as spatial resolution in the scanning direction, bolus tracking techniques and high iodine delivery rate protocols have optimized vascular enhancement in CTA.^[9,10]

However, CTA examinations are high radiation-dose studies and carry a risk of contrast-induced nephrotoxicity. Motion and beam hardening artifacts are still concerns.^[7,10]

Doppler ultrasonography is the first imaging modality used to characterize maxillofacial superficial lesions and their haemodynamic conditions; despite this, Doppler ultrasonography is not able to depict the real extension and, most importantly, the vascular anatomy.^[11]

MR angiography

- ✓ A Magnetic resonance imaging technique used to visualize the blood vessels.
- ✓ Contrast-enhanced MRA accentuated the signal from inflowing blood via the T1 shortening effect of gadolinium, resulting in improved MRA.
- ✓ Although contrast-enhanced MRA may distinguish arterial from venous components of the vascular anomaly, the exam can be technically challenging due to the variability of contrast arrival.^[12,13]

TRICKS MRA

In 1996 an MR angiographic technique, referred to as 3D TRICKS (3D time-resolved imaging of contrast kinetics) has been developed by Korosec FR. et al.^[14]

Time resolved imaging of contrast kinetics (TRICKS) MR angiography (MRA) is an approach of contrast enhanced MRA that acquires multiple 3D volumes during the passage of contrast agent bolus that can capture the dynamic filling of the arteries and veins similar to DSA in which the center of k-space is oversampled, whereas higher k-space is under sampled.^[13,15]

Why TRICKS ?

- Rather than sampling all spatial data for each time frame, TRICKS uses an algorithm to sample lower spatial frequencies more often than higher spatial frequencies, and estimates

missing data by linear interpolation of values from shared data across time frames. This improves the temporal resolution

- With high temporal resolution, images that coincide with contrast uptake in the area of interest can be obtained with the course of blood flow through arterial, capillary and venous phases.^[8]

TRICKS MRA protocol

- Patients were examined in the supine position using head and neck phased array coil.
- Injection of contrast medium was implemented with automatic power injection in antecubital vein.
- The start of the acquisition was coincided with the start of intravenous contrast bolus injection.
- The images were reconstructed in the maximum intensity projection (MIP) and volume rendering (VR). The source and reconstructed images were transferred to a commercially available workstation (Advantage for Windows, version 4.1; GE Healthcare).^[8]

MACHINE SPECIFICATIONS

1.5-T MR scanner(Signa Horizon Echo Speed, GE Healthcare), equipped with 25 mT gradient and slew rate of 70 MT/s.⁽⁸⁾

Contrast agent

- ✓ Gadopentate dimeglumine (Magnevist; Schering, Berlin, Germany).
- ✓ dose of (0.1 mmol/kg) was injected at a flow.
- ✓ rate of 3 mL/s followed by saline flush of 25 mL.

IMAGE ANALYSIS

Arteriovenous vascular malformation. Volume rendering image of TRICKS-MRA shows large nidus of tangled vessels (arrowhead) is seen in the cheek with feeder (long arrow) from the superficial temporal artery and venous drainage (short arrow) in the internal jugular vein.

Sagittal MIP images at different phases show the dilated arterial feeder (long arrow), nidus (arrowhead) and drained veins (short arrow). (figure 1).^[8]

MRI examination in another case shows a mass lesion close to the anterior margin of the right masseter muscle (figure 2(a-c)).^[16]

Time-resolved imaging of contrast kinetics (TRICKS) images (figure 2 (d)) document a small tissue component with an early arterial enhancement, while the majority of the lesion is characterized by a slow venous enhancement (arrows).

In TRICKS images after embolization, the residual component of haemangioma is evident (arrows).

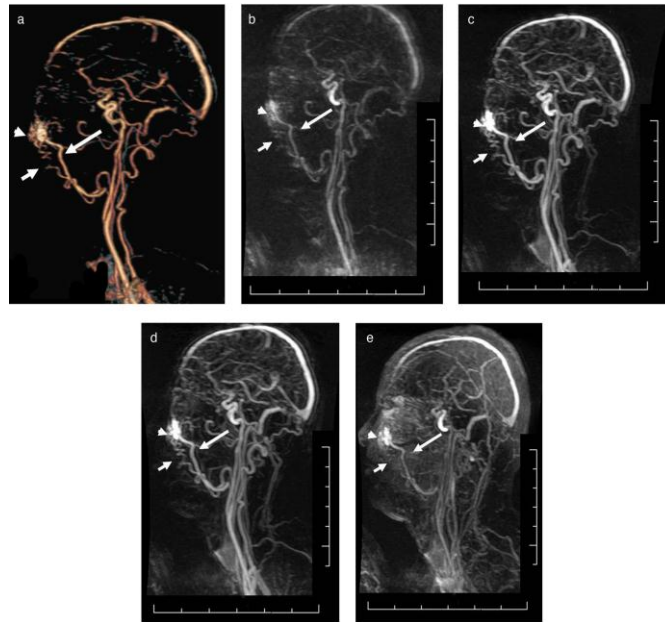


FIGURE 1 Arteriovenous vascular malformation. (a) Volume rendering image of TRICKS-

MRA shows large nidus of tangled vessels (arrowhead) is seen in the cheek with single arterial feeder (long arrow) from the superficial temporal artery and venous drainage (short arrow) in the internal jugular vein. (b–e) Sagittal MIP images at different phases show the dilated arterial feeder (long arrow), nidus (arrowhead) and drained veins (short arrow).

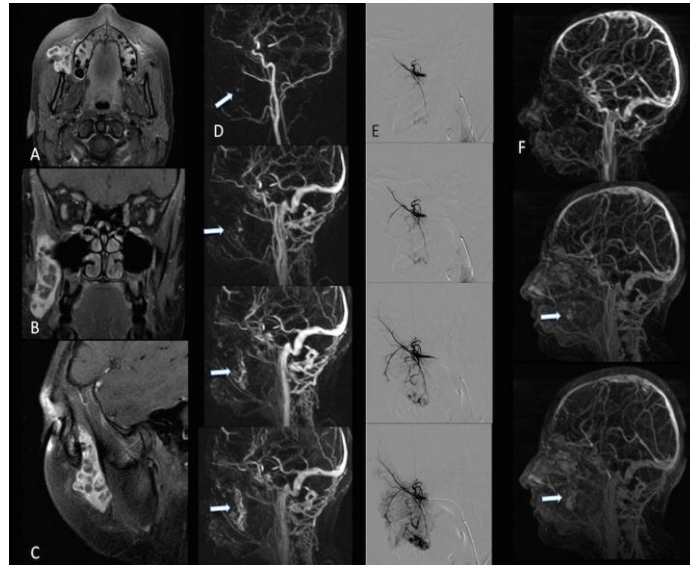
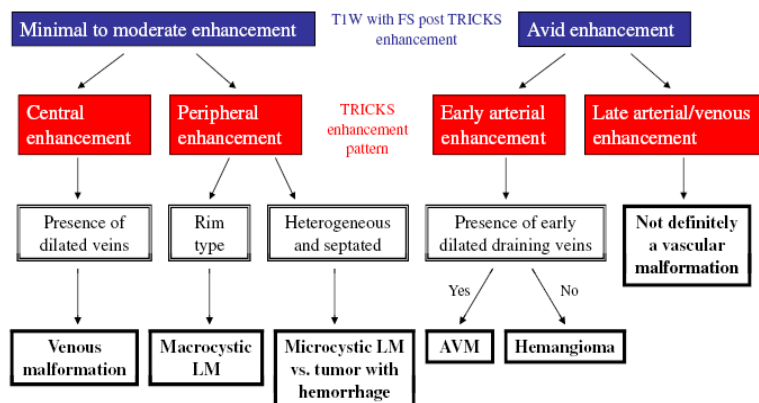


FIGURE 2 A Patient with tenderness and occasional swelling of the right cheek of about 1 month duration. MRI examination shows a mass lesion close to the anterior margin of the right masseter muscle (a–c). Time-resolved imaging of contrast kinetics (TRICKS) images (d) document a small tissue component with an early arterial enhancement, while the majority of the lesion is characterized by a slow venous enhancement (arrows). Digital subtraction radiography confirms these findings [selected angiogram of internal maxillary artery, (e)]. In TRICKS images after embolization (f), the residual component of haemangioma is evident (arrows).

The pathway designed to facilitate diagnosis using TRICKS MRA has been shown in flowchart 1.^[17]



Flowchart 1 Pathway designed to facilitate diagnosis

Advantages of TRICKS^[16,17]

- Provides temporal information,
- Is insensitive to variation in the shape and timing of contrast bolus,
- Has inherently high signal-to-noise,
- Can be acquired in any orientation, independent of the direction of blood flow,
- Preserves signal in regions of complex flow,
- Minimizes motion artifacts,
- Produces high-quality volume angiograms that can be reformatted or reprojected
- Allows the application of a variety of temporal postprocessing techniques.

Disadvantages of TRICK

These mainly include the high cost of the machine, its availability and also the spatial resolution is compromised with TRICKS.^[16]

CONCLUSION

TRICKS-MRA is a reliable tool for evaluation of AVMs of head and neck with respect to arterial feeders, nidus size and venous drainage.

Dynamic MRA in the form of TRICKS is a newly available imaging modality with great potential for improving the evaluation and management of patients with head and neck vascular anomalies.^[8]

REFERENCES

1. Smith WP, Prince S, Phelan S. The role of imaging and surgery in the management of vascular tumors of the masseter muscle. *J Oral Maxillofac Surg* 2005; 63: 1746–52.
2. Kim JS, Chandler A, Borzykowski R, Thornhill B, Taragin BH. Maximizing time-resolved MRA for differentiation of hemangiomas, vascular malformations and vascularized tumors. *PediatrRadiol* 2012; 42: 775–84.
3. Tanaka T, Morimoto Y, Takano H, Tominaga K, Kito S, Okabe S, et al. Three-dimensional identification of hemangiomas and feeding arteries in the head and neck region using combined phase-contrast MR angiography and fast asymmetric spin-echo sequences. *Oral Surg Oral Med Oral Pathol Oral Radiol Endod* 2005; 100: 609–13.
4. Lee BB, Baumgartner I, Berlien HP, et al. Consensus Document of the International Union of Angiology (IUA)-2013. Current concept on the management of arterio-venous management. *International Angiology* 2013; 32: 9–36.

5. Baer A, Parmar H, Dipietro M, Kasten S, Mukherji S. Hemangiomas and vascular malformations of the head and neck: a simplified approach. *Neuroimaging Clinics of North America* 2011; 21: 641–58.
6. Wu IC, Orbach DB. Neurointerventional management of high-flow vascular malformations of the head and neck. *Neuroimaging Clinics of North America* 2009; 19: 219–40.
7. Niimi Y, Song JK, Berenstein A. Current endovascular management of maxillofacial vascular malformations. *Neuroimaging Clinics of North America* 2007; 17: 223–37.
8. Razek AA, Gaballa G, Megahed AS, Elmogy E. Time resolved imaging of contrast kinetics (TRICKS) MR angiography of arteriovenous malformations of head and neck. *Eur J Radiol.* 2013; 82(11): 1885-1891
9. Baer A, Parmar H, Dipietro M, Kasten S, Mukherji S. Hemangiomas and vascular malformations of the head and neck: a simplified approach. *Neuroimaging Clinics of North America* 2011; 21: 641–58.
10. Tao Q, Bhatia LVB, Qiao KS, Zheng B, Chen CQZF. Three-dimensional CT angiography for the diagnosis and assessment of arteriovenous malformations in the oral and maxillofacial region. *Journal of Cranio-Maxillo-Facial Surgery* 2010; 38: 32–7.
11. Gold L, Nazarian LN, Johar AS, Rao VM. Characterization of maxillofacial soft tissue vascular anomalies by ultrasound and color Doppler imaging: an adjuvant to computed tomography and magnetic resonance imaging. *J Oral Maxillofac Surg* 2003; 61: 19–31.
12. Wheaton A, Miyazaki M. Non-contrast enhanced MR angiography: physical principles. *Journal of Magnetic Resonance Imaging* 2012; 36: 286–304.
13. Blackham K, Passalacqua M, Sandhu G, Gilkeson R, Griswold M, Gulani V. Applications of time-resolved MR angiography. *American Journal of Roentgenology* 2011; 196: W613–20.
14. Korosec FR, Frayne R, Grist TM et al. Time resolved contrast enhanced 3D MR angiography. *Magn Reson Med* 1996; 36: 341-351.
15. Grist TM, Mistretta CA, Strother CM, Turski PA. Time-resolved angiography: past, present, and future. *Journal of Magnetic Resonance Imaging* 2012; 36: 1273–86.
16. A Romano, 2F Tavanti, 2M C Rossi Espagnet, 3V Terenzi, 3A Cassoni, 4G Suma, The role of time-resolved imaging of contrast kinetics (TRICKS) magnetic resonance angiography (MRA) in the evaluation of head–neck vascular anomalies: a preliminary experience *Dentomaxillofacial Radiology* (2015); 44: 20140302.

17. Kim JS, Chandler A, Borzykowski R, Thornhill B, Taragin BH. Maximizing time-resolved MRA for differentiation of hemangiomas.