

EFFECTS OF HIBISCUS SABDARIFFA CALYX EXTRACT ON MALE REPRODUCTIVE ORGAN WEIGHT AND TESTOSTERONE IN NORMAL WISTAR RAT

Njoku-Oji N. N.^{1*}, Omoloye G. A.¹, Sobanke A.O.¹, Umahi G. O.², Uchefuna R. C.¹, Ifegwu N. O.³

¹Physiology Department, Faculty of Basic Medical Sciences, Nnamdi Azikiwe University, Nnewi Campus, Anambra State, Nigeria.

²Physiology Department, Faculty of Medicine, Ebonyi State University, Abakaliki, Nigeria.

³Anatomy Department, College of Health Sciences, Abia State University Uturu, Nigeria.

ABSTRACT

The continuous use of plants in folklore for reproductive health and the traditional belief of *Hibiscus sabdariffa* as aphrodisiac have prompted this research work. Hence, the effect of oral administration of aqueous extract of *Hibiscus sabdariffa* for fourteen (14) days on testicular and epididymal weight as well as serum testosterone level of albino male rats was investigated. Twenty mature male albino rats weighing between 150 and 200g were grouped into four groups (A, B, C and D) of five rats each. Group A was the control group and received distilled water only throughout the duration of the experiment. Groups B, C and D were the test groups and received 200, 400 and 600 mg/kg body weight of the extract respectively for 14 days, feed and water were supplied *ad-libitum*. At the end of extract administration, the animals

were fasted overnight and were sacrificed the next morning under light diethylether anaesthesia. Blood samples were collected by cardiac puncture for determination of serum testosterone levels, while the testes and epididymes were harvested and their weights determined. Results revealed no significant increase ($p > 0.05$) in testicular weight in group B (1.35 ± 0.15) when compared to control (0.778 ± 0.22). However, groups C (1.404 ± 0.03) and D (1.436 ± 0.05) showed significant increase ($p < 0.05$) in the testicular weight when compared to control group. No significant difference ($p > 0.05$) was observed in the epididymal weight in group B (1.25 ± 0.77) when compared to control group (0.912 ± 0.77).

Article Received on
14 May 2018,

Revised on 05 June 2018,
Accepted on 26 June 2018

DOI: 10.20959/wjpr201813-11344

*Corresponding Author

Njoku-Oji N. N.

Physiology Department,
Faculty of Basic Medical
Sciences, Nnamdi Azikiwe
University, Nnewi Campus,
Anambra State, Nigeria.

Groups C (1.30 ± 0.18) and D (1.32 ± 0.14) showed significant increase ($p < 0.05$) in epididymal weight when compared to control group (0.912 ± 0.77). No significant difference ($p > 0.05$) in serum testosterone was observed in groups B (0.04 ± 0.01) and C (0.68 ± 1.05) when compared to control (0.04 ± 0.01). However, Group D (1.84 ± 1.05) showed a significant increase in serum testosterone level when compared to control (0.04 ± 0.01). The result therefore justifies the folklore claims that HS is an aphrodisiac and can be used to improve fertility.

KEYWORDS: Testes, testosterone, epididymes, fertility, *Hibiscus sabdariffa*, aqueous calyx.

INTRODUCTION

In developing countries, 80% of the population continues to use medicinal plants and plant products in handling primary medical problems due to their accessibility, availability and affordability. Plants have been used to influence fertility since antiquity (Simpson *et al.*, 2001). Some plant-derived compounds (flavonoids and lignans such as secoisolariciresinol from flaxseed and raspberry) can mimic the biologic effects of endogenous hormones by binding to their nuclear receptor or regulating the activities of key enzymes of their metabolisms: cytochrome P450 aromatase; 17- betahydroxysteroid deshydrogenase (Kurzer and Xu, 1997; Dixon, 2004). A variety of plants are claimed to have reproductive regulating properties and a few has been tested for such effect (Telefo *et al.*, 2002). One of the plants that have been given extensive study for the last two decades is *Hibiscus sabdariffa*.

Hibiscus sabdariffa Linn (HS) is a shrub that belongs to the family *Malvaceae*. It is native to tropical Africa and can also be found in India and South-east Asia including Thailand and Malaysia (Mahadevan and Kamboj, 2009). Its common names include; Roselle, Sorrel, Jamaica sorrel, India sorrel, Jelly okra and Florida cranberry (Mohamed *et al.*, 2012). In Nigeria, the aqueous extract of the calyx is prepared and taken as beverage after adding spices and flavoring agents. This beverage popularly known as 'Zobo' has received widespread acceptance and has replaced canned and bottled carbonated drinks in many communities in Nigeria. It is now served in occasions as part of refreshment in Nigeria. HS is enriched in high antioxidant constituents, mainly flavonoids and vitamin C (Hirunpanich *et al.*, 2006; Tsai *et al.*, 2002). Other constituents are; anthocyanins, organic acids, Na⁺, vitamins A and Fe (Morton, 1987; Daffalah and Al-Mustafa, 1996; Appel, 2003; Adigun *et al.*, 2006). HS is a valuable source of traditional medicine (Ubani *et al.*, 2010).

Decoctions and aqueous calyx extract of HS has been claimed as an aphrodisiac in folklore medicine (Perry, 1980). They are also widely believed to be effective in the treatment of a variety of ailments including hypertension, hyperlipidaemia, obesity and diabetes (Perry, 1980; Watt *et al.*, 1962). Its antihypertensive (Onyenekwe *et al.*, 1999; Odigie *et al.*, 2003; Mojiminiyi *et al.*, 2007; Ajay *et al.*, 2007; Herera-Arellano, 2007), hypolipidaemic (Farombi and Ige, 2007; Hirunpanich *et al.*, 2006; Carvajal - Zarrabal *et al.*, 2005), anti-obesity (Alarcon-Aguilar *et al.*, 2007; Kim *et al.*, 2007) and anti-diabetic (Farombi and Ige, 2007; Lans, 2006) effects have been scientifically proven. HS is consumed by all sorts of people including male and female, young and old without considering its effect in reproductive health especially on male reproduction.

About 30-50% infertility cases have been attributed to problems with males (Ekwere *et al.*, 2007). The use of aphrodisiac however, has proven relevant in management of many forms of infertility. As an aphrodisiac, HS is expected to be effective in elevating serum testosterone levels among other features (Gooren and Saad, 2006).

However, the dearth of published information on the effects of HS on the male reproductive organ weight and testosterone in normal male albino rats has prompted this research work. Thus, this study is hoped to provide more information on the effects of HS on these reproductive parameters and also give scientific evidence to the claim that HS is an aphrodisiac in folklore medicine.

MATERIALS AND METHODS

Plant Material and Extract Preparation: Dried mature red calyces of *Hibiscus sabdariffa* were purchased from a popular market in Nnewi, Anambra state, Nigeria. The plant was identified and authenticated by Mr. P.O. Ugwuozor of Department of Botany, Nnamdi Azikiwe University, Awka Anambra State. Some particles such as the flowers and seeds of the plant were hand-picked and removed from the calyces. 400g of the calyx was ground into coarse powder using an electric blender. The ground sample was then macerated in 2litres of lukewarm water for a period of 48hours. The mixture was sieved twice using a piece of clean white cotton material and then, further filtered using the Wattman no. 1 filter paper. The filtrate was concentrated using oven with extractor fan at the temperature of 50⁰c. Then the crude extract was stored in the refrigerator for use. The extract was reconstituted into 200mg, 400mg and 600mg/kg body weight when needed. The LD₅₀ of HS calyx extract in rats was found to be above 5000mg/kg body weight (Onyenekwe *et al.*, 1999).

Experimental Animals and Extract Administration

Twenty mature male albino rats weighing between 150- 200g were used for this study. The rats were housed in well ventilated cages and acclimatized for 2 weeks in the animal house of the Department of Physiology, Nnamdi Azikiwe University, Nnewi campus under controlled environmental conditions. The animals were provided standard rat pellet feed and tap water *ad libitum*. At the end of acclimatization, the animals were grouped into four groups labeled A- D of five rats each. Group I was the control group and received distilled water only. Groups II-IV were the test groups and received 200mg, 400mg and 600mg/kg body weight of the extract respectively for 14 days by oral gavage. All procedures used in this study conformed to the guiding principles for research involving animals as recommended by the Declaration of Helsinki and the Guiding principles in the Care and Use of animals (American Physiological Society, 2002). At the end of extract administration, the animals were fasted overnight and were sacrificed the next morning under light diethylether anaesthesia. Blood samples were collected by cardiac puncture for determination of testosterone levels.

Determination of reproductive organ weight

Dissection was done transversely across the peritoneum and the testes was pushed into the abdominal region and extracted after the ducts were carefully cut. The epididymis was separated carefully from the testis. Both testes as well as the epididymis were weighed using the Electronic balance JA-410 and the average derived.

Serum Testosterone Assay

Blood samples were left for 60 minutes to clot and then centrifuged for 10 minutes at 2500rpm. The obtained clear sera were stored using plain sample bottles, at -4°C. The testosterone level was measured by enzyme-linked immunosorbent assay method using the Testosterone Enzyme Immunoassay Test kit (BC-1115).

Statistical Analysis

All data were statistically analyzed using SPSS version 20.0. Results were expressed as Mean \pm standard error of mean (M \pm SEM). One way analysis of variance (ANOVA) followed by Bonferroni's Post-hoc test were used for data comparison. Results were considered statistically significant at $p < 0.05$.

RESULTS

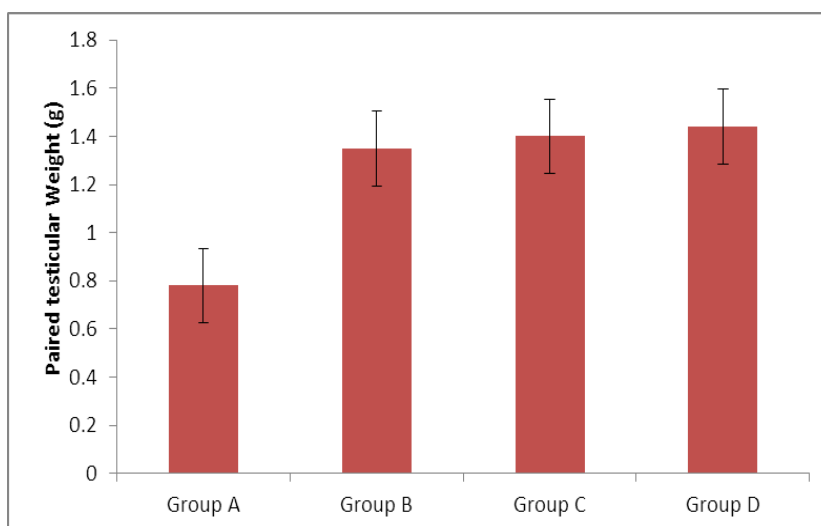


Figure. 1: Effect of aqueous of HS calyx extract on testicular weight of albino rat There was no significant increase ($p > 0.05$) in testicular weight in group B (1.35 ± 0.15) when compared to control (0.778 ± 0.22). However, groups C (1.404 ± 0.03) and D (1.436 ± 0.05) showed significant increase ($p < 0.05$) in the testicular weight when compared to control group.

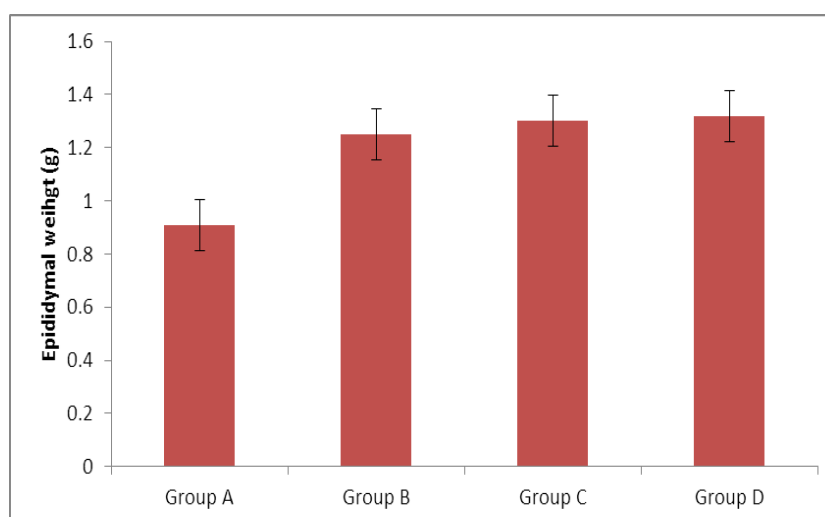


Figure. 2: Effect of aqueous of HS calyx extract on epididymal weight of albino rat No significant difference ($p > 0.05$) was observed in the epididymal weight in group B (1.25 ± 0.77) when compared to control group (0.912 ± 0.77). Groups C (1.30 ± 0.18) and D (1.32 ± 0.14) showed significant increase ($p < 0.05$) in epididymal weight when compared to control group (0.912 ± 0.77).

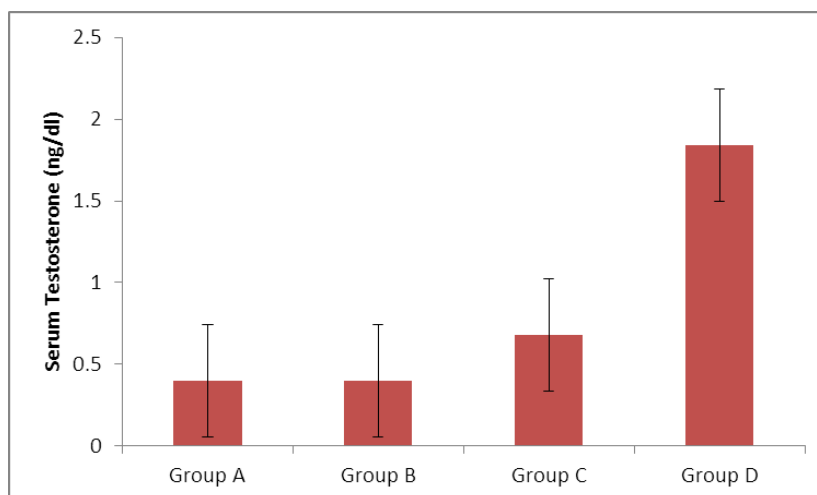


Figure. 3: Effect of aqueous of HS calyx on serum testosterone of albino rats No significant difference ($p>0.05$) in serum testosterone was observed in groups B (0.04 ± 0.01) and C (0.68 ± 1.05) when compared to control (0.04 ± 0.01). However, Group D (1.84 ± 1.05) showed a significant increase in serum testosterone level when compared to control (0.04 ± 0.01).

DISCUSSION

The results of the present study showed that the aqueous calyx extract of HS caused significant increase in testicular and epididymal weight as well as serum testosterone level at increased doses. This indicates a positive effect of the extract on male reproductive parameters.

The significant increase in the testicular weight may be as a result of the presence of high concentration of anthocyanin in the calyx of *Hibiscus sabdariffa* (Mohamed *et al.*, 2007). Anthocyanin caused increase in testicular weight as reported by Jang *et al.*, (2012). It could also be as a result of increased testosterone level observed in this study since there is a positive correlation between testicular/epididymal weight and serum testosterone (Setty *et al.*, 1997, Howell-Skalla *et al.*, 2002, Morakinyo *et al.*, 2008). Androgens especially testosterone is necessary for development, growth and normal functioning of the testis and male accessory reproductive organs, it is clear that increase in testosterone aid the increase in weight of testis and epididymis.

The increase in testosterone level observed in this study especially at increased dose could be related to high anthocyanin level present in the extract. Anthocyanin has been reported to increase serum testosterone level in rats (Akpanthah *et al.*, 2003; Oluyemi *et al.*, 2007). The

mechanism to this effect is thought to be through the anti-oxidant effect of anthocyanin which has been reported to cause reduction in malondialdehyde concentration thereby reducing the reactive oxygen species released from lipid peroxidation breakdown in the biological system, having potential toxic effect on the body system (Morakinyo *et al.*, 2008). The increase in serum testosterone observed in this study may also be attributed to its high content of vitamin C (Hirunpanich *et al.*, 2006; Tsai *et al.*, 2002). Several studies have shown that vitamin C counteract the testicular oxidative stress induced by exposure to pro-oxidants (John and Shaun 2005, Rekha *et al.*, 2011), also it has been reported that deficiency of vitamin C led to state of oxidative stress in the testes that disrupt both spermatogenesis and the production of testosterone. Vitamin C was able to ameliorate the sequence of cryptorchidism and reduce testicular germ cells apoptosis in a study hence, increase in mean value of number of germ cells (Al- Asadi, 2011). Greenspan and Stawler (1997) and Gelain *et al.*,(2005) reported that, testosterone synergizes with follicle stimulating hormone for the stimulation of the spermatogenic cells to undergo successful spermatogenesis in the seminiferous tubules, sperm maturation in the epididymes and the secretory activity of the accessory sex glands. Hence this plant extract can ameliorate the problem of infertility in males.

The non significant increase in the reproductive parameters observed in the groups that received 200mg/kg suggests that at this concentration, the constituents of the extract responsible for the increase in reproductive parameters measured were not enough to induce any change in reproductive parameters. This result is in agreement with a previous work done by Ali *et al.*, (2012) who reported no significant difference in the testosterone level of rats fed with 200mg/kg body weight of calyx extract of HS when compared with the control.

It can therefore be concluded that the aqueous extract of HS has a positive effect on the testicular/epididymal weight and serum testosterone level. This therefore justifies the folklore claims that HS is an aphrodisiac and can be used to improve fertility.

REFERENCES

1. Simpson, M., Parsons, M., Greenwood, J., Wade, K. Raspberry leaf in pregnancy: its safety and efficacy in labor. *J. Midwifery Womens Health*, 2001; 46: 51–59.
2. Kurzer, M.S., Xu, X. Dietary Phytoestrogens. *Annu. Rev. Nutr.* 1997; 17: 353–381
3. Dixon, R.A., Phytoestrogens. *Annu. Rev. Plant Biol.*, 2004; 55: 225–261.

4. Telefo, P.B., P.F. Moundipa and F.M. Tchouanguép. Oestrogenicity and effect on hepatic metabolism of the aqueous extract of leaf mixture of *Aloe buettneri*, *Dicliptera verticillata*, *Hibiscus macranthus* and *Justicia insularis*. *Fitoterapia*, 2002; 73: 472–478
5. Mahadevan N, Kamboj P. *Hibiscus sabdariffa* Linn. – An overview. *Nat Prod Radiance*, 2009; 8: 77-83.
6. Mohamed, B. B., Sulaiman, A. A., Dahab, A. A. Roselle (*Hibiscus sabdariffa* L.) in Sudan, cultivation and their uses. *Bulletin of Environment, Pharmacology and Life Sciences*, 2012; 1(6): 48-54.
7. Hirunpanich V, Utaipat A, Morales NP, Bunyapraphatsara N, Sato H, Herunsale A et al. Hypocholesterolemic and antioxidant effects of aqueous extracts from the dried calyx of *Hibiscus sabdariffa* L. in hypercholesterolemic rats. *J Ethnopharmacol*, 2006; 103: 252-60.
8. Tsai PJ, McIntosh J, Pearce P, Camden B, Jordan BR Anthocyanin and antioxidant capacity in Roselle (*Hibiscus sabdariffa* L.) extract. *Food Res Int.*, 2002; 35: 351-6.
9. Morton, J.F. Roselle. In: *Fruits of warm climate*. Juliaf, Morton and Miami, Florida., 1987: 281-286.
10. Daffalah, A.A. and Z. Al-Mustafa: Investigation of the anti-inflammatory activity of *Acacia nilotica* and *Hibiscus sabdariffa*. *Am. J. Chin. Med.*, 1996; 24: 263-269.
11. Appel, S.D. Red sorrel, *Hibiscus sabdariffa*- The other “cranberry”. *Plants and Gardens News.*, 2003; 18: 2.
12. Adigun, M.O., O.D. Ogunidipe, J.I. Anetor and A.O. Odetunde. Dose-dependent changes in some haematological parameters during short-term administration of *Hibiscus sabdariffa* calyx aqueous extract (zobo) in Wistar albino rats. *Afr. J. Med. Med. Sci.*, 2006; 35: 73-77.
13. Ubani C. S, Joshua P. E, Oraeki A. N. Influence of aqueous extract of *Hibiscus sabdariffa* calyces on lipid profile of phenobarbitone induces wistar albino rats. *J Pharm Res.*, 2010; 3: 319-24.
14. Perry, L.M. (1980). *Medicinal plants of east and Southeast Asia*. MIT press, Cambridge.
15. Watt, J.M. and M.G. Breyer – Brandwijk (1962). *The medicinal and poisonous plants of southern and eastern Africa*. 2nd Edn. E and S Livingstone Ltd, Edinburgh and London.
16. Onyenekwe, P.C., Ajani, E.O., Ameh, D.A., Gamammiel, K.S. Antihypertensive effect of roselle (*Hibiscus sabdariffa*) calyx infusion in spontaneously hypertensive rats and a comparison of its toxicity with that in Wistar rats. *Cell BiochemFunc*, 1999; 17: 199–206.

17. Odigie, I.P., R.R. Ettarh and S.A. Adigun. Chronic administration of aqueous extract of *Hibiscus sabdariffa* attenuates hypertension and reverses cardiac hypertrophy in 2K-1C hypertensive rats. *J. Ethnopharmacol*, 2003; 86: 181-5.
18. Mojiminiyi, F.B.O., M. Dikko, B.Y. Muhammad, P.D. Ojobor, O.P. Ajagbona, R.U. Okolo, U.V. Igbokwe, U.E. Mojiminiyi, M.A. Fagbemi, S.O. Bello and T.J. Anga. Antihypertensive effect of an aqueous extract of the calyx of *Hibiscus sabdariffa* *Fitoterapia*, 2007; 78: 292-297.
19. Ajay, M., H.J. Chai, A.M. Mustafa, A.H. Gilani and M.R. Mustafa. Mechanisms of the anti-hypertensive effect of *Hibiscus sabdariffa* L. calyces. *J. Ethnopharmacol*, 2007; 109: 388-93.
20. Herera-Arellano, A., J. Miranda-Sanchez, P. Avila-Castro, S. Herrera-Alvarez, J.E. Jimenez-Ferrer, A. Zamilpa, R. Roman-Ramos, H. Ponce-Monter and J. Tortoriello. Clinical effects produced by a standardized herbal medicinal product of *Hibiscus sabdariffa* on patients with hypertension. A randomized, double-blind, lisinopril controlled clinical trial. *Planta Med.*, 2007; 73: 6-12.
21. Farombi, E.O. and O.O. Ige. Hypolipidemic and antioxidant effects of ethanolic extract from dried calyx of *Hibiscus sabdariffa* in alloxan-induced diabetic rats. *Fundam. Clin.Pharmacol*, 2007; 21: 601-9.
22. Carvajal-Zarrabal, O., S.M. Waliszewski, D.M. Barradas- Demitz, Z. Orta-Flores, P.M. Hayward-Jones, C. Nolasco-Hipolito, O. Angulo-Guerrero, R. Sanchez- Ricano, R.M. Infanzon and P.R. Trujillo. The consumption of *Hibiscus sabdariffa* dried calyx ethanolic extract reduced lipid profile in rats. *Plant Foods Hum. Nutr.*, 2005; 60: 153-9.
23. Alarcon-Aguilar, F.J., A. Zamilpa, M.D. Perez-Garcia, J.C. Almanza-Perez, E. et al, Effect of *Hibiscus sabdariffa* on obesity in MSG mice. *J. Ethnopharmacol.*, 2007; 114: 66-71.
24. Kim, J.K., H. So, M.J., Youn, H.J. Kim, Y. Kim, C. Park, S.J. Kim, Y.A. et al. *Hibiscus sabdariffa* L. water extract inhibits the adipocyte differentiation through the PI3- K and MAPK pathway. *J. Ethnopharmacol*, 2007; 114: 1- 31.
25. Lans, C.A., Ethnomedicines used in Trinidad and Tobago for urinary problems and diabetes mellitus. *J. Ethnobiol. Ethnomed*, 2006; 13: 2-45.
26. Akpantah A. O, Oremosu A.A, Ajala M.O, Noronha CC, Okan lawon A.O. *Nig. J. Health Biomed. Sci.*, 2003; 2: 40-46.
27. Al-Asadi. Effect of Vitamin C on Apoptotic germ cells of Cryptorchid testis in rabbits. *Bas. J. vet. Res.*, 2011; 10(1): 67-81.

28. Ali, M.S., Salih, W.M., Mohamed, A.H., Homeida, A.M. Investigation on the antispasmodic potential of *Hibiscus sabdariffa* calyces. *J Ethnopharmacol*, 1991; 31: 249–257.
29. American Physiological Society (APS). Guiding Principles for Research involving Animals and Human Beings. *American Journal of Physiology*, 2002; 283: R281-3.
30. Duke, C.T. and F.J. Francis. Anthocyanins of Roselle (H.S.L.) *J. Food Sci.*, 1973; 38: 810-812.
31. Ekwere, P.D., Archibong, E I, Bassey, E E, Ekabua, J E, Ekanem, E I and Feyi-Waboso, P. Infertility among Nigerian couples as seen in Calabar. *Port Harcourt Medical Journal*, 2007; 2: 35-40.
32. Emelike, C. U., Dapper, D. V. Biochemical effects of oral administration of aqueous extract of *Hibiscus sabdariffa* on Wistar albino rats. *IOSR Journal of Dental and Medical Sciences*, 2013; 9(1): 35-39.
33. Gelain, D.P., E.A Casali, and F. Dal- Pizzol, Effect of follicle stimulating hormone and vitamin A upon purinergic secretion by rat sertoli cells. *Molecular Cell Biochemistry*, 2005; 278: 185 195.
34. Gooren, L.J.G. and Saad, F., Recent insights into androgen action on the anatomical and physiological substrate of penile erection. *Asian journal of andrology*, 2006; 8(1): 3–9.
35. Greenspan, F.S. and G.J. Stawler. (1997). *Basic and clinical endocrinology*. McGraw Hill, New York.
36. Howell-Skalla L,A., Callet M.R.L., Ramsey M.A., Bahr J.M. Seasonal changes in testicular size and serum LH, Prolactin and testosterone concentrations in male polar bears (*Ursus maritimus*). *Reproduction*, 2002; 123: 729-733.
37. Jang H, Kim SJ, Yuk SM, Han DS, Ha US, Hong SH, Lee JY et al (2012). Effect of antocyanin extracted from black soyabean seed coat on spermatogenesis in a rat variocoele-induced model.
38. John R.A and Shaun. R.(2005). Antioxidant system and oxidative stress in the testis. NSW, Australlia. Email:John Altken .newcastle.edu.au.
39. Mohamed R, Fernandez J, Pineda M, Aguilar M. Roselle (*Hibiscus sabdariffa*) seed oil is a rich source of gamma-tocopherol. *Journal of Food Science*, 2007; 72(3): S207-11.
40. Oliver, B. *Medicinal plants in Nigeria*. Nigerian College of arts, Sci. Technol. Ibadan, 1962: 16-42.
41. Onyenekwe, P.C., E.O. Ajani, D.A. Ameh and K.S. Gamammiel. Antihypertensive effect of roselle (*Hibiscus sabdariffa*) calyx infusion in spontaneously hypertensive rats and a

- comparison of its toxicity with that in Wistar rats. *Cell. Biochem. Func.*, 1999; 17: 199-206.
42. Rekha D. K., Tripathi Y., Raghuveer C. V., Sheila R. P., Ramaswamy C, Priya K. Role of vitamin C as an antioxidant in cadmium chloride induced testicular Damage. *International Journal of Applied Biology and Pharmaceutical Technology*, 2011; 2(3): 484-488.
43. Setty BS, Riar SS, Kar AB. Androgenic control of epididymal function in rhesus monkey and rabbit. *Fert Steril*, 1977; 22: 674–81.