

IDENTIFICATION OF THE POTENTIAL INDICATIONS AND SHORT-TERM OUTCOME OF INTRAVITREAL INJECTION OF BEVACIZUMAB AT REGIONAL REFERRED EYE HOSPITAL IN MADINAH, SAUDI ARABIA 2016

Ghaida A. Mohammed Aziz^{1*}, Ghaida M. Alahmadi², Haifa A. Mohammed Aziz³, Mohammed A. Jabri⁴, Abdulaziz A. Alhosaini⁵ and Maan Al-barry⁶

¹Physician at Prince Mohammed bin Abdulaziz Hospital, Madinah, Saudi Arabia.

²Ophthalmology Resident at Ohud Hospital, Madinah, Saudi Arabia.

³Medical Intern at Taibah University, Madinah, Saudi Arabia.

⁴Medical Student at Taibah University, Madinah, Saudi Arabia.

⁵Emergency Medicine Resident at King Abdulaziz Medical City, Riyadh, Saudi Arabia.

⁶MD.FRCS Consultant Anterior Segment and Uveitis, Assistant professor and chairman of the Department of Ophthalmology, Taibah University.

Article Received on
30 October 2018,

Revised on 20 Nov. 2018,
Accepted on 11 Dec. 2018

DOI: 10.20959/wjpr20191-10583

***Corresponding Author**

**Ghaida A. Mohammed
Aziz**

Physician at Prince
Mohammed bin Abdulaziz
Hospital, Madinah, Saudi
Arabia.

ABSTRACT

Background: Bevacizumab is a monoclonal antibody that binds to all kinds of vascular endothelial growth factor (VEGF) and is successfully used as a systemic drug in treatment of cancers.^[1] Several previous studies have revealed the usefulness of the intravitreal injection of bevacizumab in treatment neovascularization and macular edema secondary to several eye diseases.^[2-11] **Purpose:** To point out the indications and assess short-term outcome of bevacizumab intravitreal injection at Regional Referred Eye Hospital in Madinah Area, Saudi Arabia. **Methods:** The study included 59 eyes of the studied patients submitted to intravitreal injection of bevacizumab at Regional Referred Eye Hospital in Madinah Area, Saudi Arabia, during the period from

June to December 2015. At baseline, visual acuity and optical coherencetomography (OCT) were measured and data sheet was filled for each studied patient. The outcome variables in terms OCT thickness in micrometers and visual acuity were measured three months after injection. The data were analyzed by appropriate statistical tests. **Results:** Of the 59 studied eyes, the majority 35 (59.3%) were diagnosed as diabetic macular edema (DME), 9 (15.3%)

as proliferative diabetic retinopathy (PDR), 5 (8.5%) as combined PDR and vitreous hemorrhage (VH), 4 (6.8%) as combined DME and PDR, 2 (3.4%) as choroidal neovascularization (CNV) secondary to age-related macular degeneration, 2 (3.4%) as macular edema secondary to central retinal vein occlusion (CRVO), 1 (1.7%) as macular edema secondary to branch retinal vein occlusion (BRVO) and 1 (1.7%) as neovascular glaucoma. Compared to baseline mean OCT thickness, there was a statistically significant decrease in mean OCT thickness measured three months after injection. It was markedly decreased in patients aged ≤ 60 years (54.2%), male patients (37.2%), type II diabetics (52.5%), best corrected visual acuity of ≥ 0.1 (45.7%), non-hypertensive (42.3%), and those with DME (38.9%), with PDR (8.4%), with PDR and VH (8.4%) and those with DME and PDR (6.7%) more than 10%. Moreover, the visual acuity was improved in 9 (43%) out of 21 eyes with baseline visual acuity < 0.1 Decimal. **Conclusions:** Diabetic macular edema was the commonest indication followed by proliferative diabetic retinopathy. In addition, the study confirms the accumulating evidence of the usefulness and short-term efficacy of intravitreal injection of bevacizumab. The study suggests the need for further investigations with larger multicenter randomized studies in our region and a longer follow up to verify if this improvement is sustainable or not. However, the major concern is the need for increasing awareness about the importance of diabetes control and its impact in our region.

KEYWORDS: Intravitreal, Macular edema, Bevacizumab, Diabetes mellitus, Saudi Arabia.

INTRODUCTION

Bevacizumab is a monoclonal antibody that binds to all kinds of vascular endothelial growth factor (VEGF) and is successfully used as a systemic drug in the treatment of cancers.^[1] VEGF is known to have a pivotal role in the process of neovascularization and increasing vascular permeability in diabetic eyes.^[2] Apart from laser photocoagulation, which is the primary treatment modality, intravitreal injection of bevacizumab was used widely in treatment of various types of macular edema. Several previous studies have revealed the usefulness of the procedure in decreasing macular edema secondary to central retinal vein occlusion, fibrovascular proliferation secondary to proliferative diabetic retinopathy (PDR), and choroidal neovascularization (CNV) secondary to age-related macular degeneration and secondary to vogt-koyanagi-harada syndrome (VKH).^[3-12]

In animal studies, no toxicity was noted following intravitreal bevacizumab injection in albino rabbit retina at different concentrations up to 2.5 mg.^[13] In human studies, however,

some rare systemic and ocular complications have been reported. The systemic complication included increase in blood pressure, followed by cerebrovascular accidents and myocardial infarction.^[14] Endophthalmitis, a severe ocular complication, was also reported in previous studies.^[15] The prognostic value of patients' characteristics such as age, gender, and best-corrected visual acuity (BCVA) at baseline were analyzed in other studies.^[16-18] These studies identified young age, male gender, and good BCVA at baseline as favorable prognostic factors.

Although the wide indications of use of intravitreal bevacizumab injections, in the Saudi literature there was no overall collective indications of the usefulness of this intravitreal drug for variety indications. From this point of view, the present study aimed to point out the collective and frequent indications of intravitreal bevacizumab and assessing the short-term outcome of patients treated with intravitreal Bevacizumab injections at the regional referred eye Hospital in Madinah Area, Saudi Arabia.

METHODS

The present follow up study included 59 eyes of the studied patients submitted to intravitreal injection of bevacizumab at regional referred Eye Center of Ohoud Hospital in Madinah Area, Saudi Arabia during the period from June to December 2015. All patients who met the inclusion criteria at Eye Center of Ohud Hospital of both genders came for their first intravitreal bevacizumab injection and aged more than 18 years were eligible for the study. The exclusion criteria included, patients having bleeding disorder, active ocular infection, previous history of intravitreal bevacizumab, recent myocardial infarction, pregnancy and previous history of laser photocoagulation.

The visual acuity and optical coherence tomography (OCT) were measured and data sheet was filled at the baseline (one week before bevacizumab injection). OCT was done on Topcon 3D OCT 2000 (picture angle 45 degrees with an in-depth resolution of 5 micrometer) prior to procedure using the Cirrus HD-OCT device to assess the macular thickness. Intravitreal injection of 1.25 mg/0.05ml of bevacizumab was injected 3.5-4mm from limbus under local anesthesia by the Doctor in charge. Post procedure OCT was done on all studied patients three months after injection and the final outcome was determined on the basis of macular thickness in micrometers. Visual acuity was also measured.

DME was defined as retinal edema or hard exudates within 500micrometers of the center of macula, retinal edema one disc diameter or larger, any part of which was within one disc diameter of center of macula as evaluated on OCT.^[20]

All data analyses were done using statistical analysis system (SAS) software package.^[19] The data were presented as mean \pm SD for continuous variables and frequencies and percentages for categorical variables. The mean OCT diameters were compared before and after bevacizumab injections using paired *t* test. In order to compare the the percent reduction in the thickness of OCT, three months following injection of bevacizumab, among the studied patients, chi square, Fischer exact and McNemar tests were used as appropriate. P value \leq 0.05 was considered as an indicator of statistically significant difference.

Ethical consideration was taken to ensure the confidentiality and privacy of the collected data. Written consent was taken from all studied patients. Patients who were mentally not able to give consent and those refused to participate were excluded from the study. Deanship of Scientific Research Ethics Committee at Taibah University, Madinah, Saudi Arabia, approved the study protocol.

RESULTS

The study analyzed data from 59 eyes of the studied patients. The mean age of the patients was 56.7 ± 10.9 years, of them 78% were \leq 60 years old. More than one half of them (55.9%) were male. The majority of the studied patients (79.7%) were type II diabetic patients. Less than half of patients were hypertensive (39%). Of the studied subjects the majority, 35eyes (59.3%) were diagnosed as diabetic macular edema (DME), 9 eyes (15.3%) as proliferative diabetic retinopathy (PDR), 5 eyes (8.5%) as combined PDR and vitreous hemorrhage (VH), 4 eyes (6.8%) as combined DME and PDR, 2 eyes (3.4%) as choroidal neovascularization (CNV) secondary to age-related macular degeneration (ARMD), 2 eyes (3.4%) as macular edema secondary to central retinal vein occlusion (CRVO), 1 eye (1.7%) as macular edema secondary to branch retinal vein occlusion (BRVO) and 1 eye (1.7%) as neovascular glaucoma. The mean OCT macular thickness for all studied patients at their baseline was 425.2 ± 168.9 micrometers. Also, the baseline of best corrected visual acuity (\geq 0.1 Decimal) was found in 64.4% of the studied patients (table 1).

Table. 1. Characteristics of studied patients.

Characteristics*	N= 59
Age in years, mean \pm SD (Range)	56.7 \pm 10.9 (24-80)
Age in categories	
\leq 60 years	46 (78.0)
$>$ 60 years	13 (22.0)
Patients' sex	
Male	33 (55.9)
Female	26 (44.1)
Diabetes mellitus	
No	4 (6.8)
Type I	8 (13.5)
Type II	47 (79.7)
Hypertension	
No	36 (61.0)
Hypertension	23 (39.0)
Eye diseases	
DME	35 (59.3)
PDR	9 (15.3)
PDR + VH	5 (8.5)
DME + PDR	4 (6.8)
CNV	2 (3.4)
Macular edema secondary to CRVO	2 (3.4)
Macular edema secondary to BRVO	1 (1.7)
NV glaucoma	1 (1.7)
OCT in micrometers before injection, mean \pm SD (Range)	425.2 \pm 168.9 (137-862)
Visual acuity on presentation	
\geq 0.1	38 (64.4)
$<$ 0.1	21 (35.6)

*Data are presented by mean \pm SD or by n (%).

Table. 2. Comparison of mean OCT thickness before and after Bevacizumab injection by patients' characteristics: three months follow up.

Patients' characteristics	Before injection	After 3 months	P value
All studied patients (n=59)	425.2 \pm 168.9	370.5 \pm 143.7	0.04*
Age categories			
$<$ 60 years	421.7 \pm 156.5	349.5 \pm 162.7	0.03*
\geq 60 years	468.2 \pm 108.6	435.2 \pm 117.7	0.20
Patients' sex			
Male	422.3 \pm 164.5	337.7 \pm 122.6	0.01*
Female	441.7 \pm 181.7	369 \pm 152.9	0.19
Diabetes mellitus			
No	668.3 \pm 148.7	515. \pm 133.1	0.43
Type I	443.6 \pm 188.9	304.4 \pm 205.7	0.14
Type II	410.6 \pm 159.1	385.1 \pm 148.3	0.28
Hypertension			

No	407.3 ± 150.2	368.1 ± 157.2	0.21
Hypertension	465.5 ± 201.3	410.8 ± 158.5	0.25
Reasons			
DME	421.8 ± 154.2	317.3 ± 116.3	0.01*
PDR	507 ± 181.4	459.5 ± 163.4	0.15
PDR + VH	96.0 ± 214.6	337.8 ± 197.3	0.28
DME + PDR	381.7 ± 180.8	203.2 ± 37.1	0.08
CNV	624.5 ± 47.3	559.5 ± 48.7	0.95
Macular edema CRVO	453.9 ± 186.3	369.5 ± 177.2	0.04*
Macular edema BRVO	668.3 ± 148.7	515.6 ± 133.1	0.03*
NV glaucoma	513.2 ± 85.2	465.2 ± 80.5	0.04*
Visual acuity			
≥ 0.1	400.9 ± 152.1	358.9 ± 152.0	
< 0.1	500.4 ± 195.7	446.1 ± 154.6	0.04*

*Significant

Table 2 compared the mean OCT thickness of the studied patients before and after Bevacizumab injection by their characteristics. Statistically significant difference was detected between the mean OCT thickness before and after injection among all studied patients ($p= 0.04$). Also, a significant reduction in the mean OCT thickness after Bevacizumab injection was observed among patients less than 60 years ($P= 0.03$), and male patients ($p= 0.01$). Examining patients by the reason of Bevacizumab injection, the mean OCT thickness was decreased after Bevacizumab injection for studied reasons and did show statistically significant differences among patients presented with DME, Neovascular glaucoma, Macular edema secondary to BRVO, and among those patients presented with Macular edema secondary to CRVO. Patients with best corrected visual acuity of ≥ 0.1 Decimal, showed significant decrease in the macular thickness after injection ($p=0.04$).

Table 3: Reduction in OCT thickness after Bevacizumab injection by patients' characteristics: three months follow up.

Patients' characteristics	> 10 % n (%)	≤ 10 % n (%)	P value
All studied patients (n=59)	41 (69.4)	18 (30.5)	-
Age categories			
≤60 years	32 (54.2)	14 (23.7)	0.98
> 60 years	9 (15.2)	4 (6.7)	
Patients' sex			
Male	22 (37.2)	11 (18.6)	0.59
Female	19 (32.2)	7 (11.8)	
Diabetes mellitus			
No	3 (5.0)	1 (1.6)	0.45
Type I	7 (11.8)	1 (1.6)	
Type II	31 (52.5)	16 (27.1)	

Hypertension			
No hypertension	25 (42.3)	11 (18.6)	0.99
	16 (27.1)	7 (11.8)	
Reason			
DME			
PDR	23 (38.9)	12 (20.3)	
PDR + VH	5 (8.4)	4 (6.7)	
DME + PDR	5 (8.4)	0 (0.0)	
CNV	4 (6.7)	0 (0.0)	0.25
Macular edema secondary to CRVO	1 (1.6)	1 (1.6)	
Macular edema secondary to BRVO	2 (3.3)	0 (0.0)	
NV glaucoma	1 (1.6)	0 (0.0)	
	1 (1.6)	0 (0.0)	
Visual acuity			
≥ 0.1	27 (45.7)	11 (18.6)	0.72
< 0.1	14 (23.7)	7 (11.8)	

Table 3 presented the percent reduction in the macular thickness of OCT following injection of bevacizumab at three months follow up. Macular thickness after three months of injection was decreased. In the eyes of the studied patients with decreased macular thickness, there were 41 eyes (69.4%) with $\geq 10\%$ decrease in macular thickness, 18 eyes (30.5%) with $< 10\%$ decrease in macular thickness.

Although, there were no statistically significant differences in the percent reduction, the higher proportion of eyes with $> 10\%$ macular thickness reduction was among patients aged ≤ 60 years (54.2%), male patients (37.2%), type II diabetics (52.5), best corrected visual acuity of ≥ 0.1 (45.7%), non-hypertensive (42.3%), and those with DME (38.9%). The patient presented with neovascular glaucoma in this study showed more than 10% reduction in macular thickness after Bevacizumab injection.

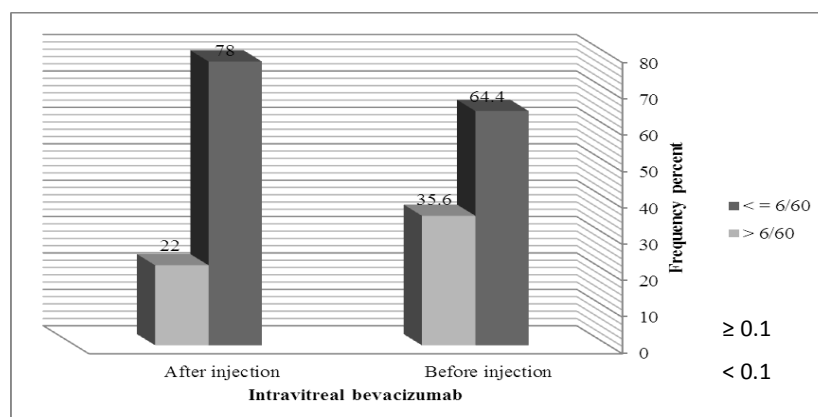


Figure 1: Comparison of visual acuity before and after Bevacizumab injection: Three months follow up.

Table 4: Comparison of visual acuity before and after Bevacizumab injection: three months follow up.

Visual acuity	Before injection n (%)	After injection n (%)	P value
≥ 0.1	38 (64.4)	46 (78.0)	0.01*
< 0.1	21 (35.6)	13 (22.0)	
Total	59	59	

*significant

Figure 1, Table 4 showed comparison of patients' visual acuity before and after bevacizumab injection. Out of the studied 59 eyes of the studied patients, there were 38 eyes (64.4) with best corrected visual acuity of ≥ 0.1 Decimal at baseline. After injection, the frequency of eyes with best corrected visual acuity was significantly increased ($p=0.01$) to reach 46 eyes (78%). Paired analyses of the above mentioned figures was revealed that 9 (43%) out of studied 21 eyes with baseline visual acuity < 0.1 were improved. Meanwhile only one eye (7.7%) of the studied 38 eyes with baseline visual acuity ≥ 0.1 was deteriorated.

DISCUSSION

The present case series follow up study included 59 eyes of the studied patients attending Ohoud Hospital, Madinah, Saudi Arabia; 35 eyes were diagnosed with DME, 9 with PDR, 5 with PDR and VH, 4 with DME and PDR, 2 with CNV secondary to ARMD, 2 with Macular edema secondary to CRVO, 1 with Macular edema secondary to BRVO and 1 with neovascular glaucoma. All cases were submitted to intravitreal injection of bevacizumab at eye center of Ohoud hospital, Madinah, Saudi Arabia during six-months study period from June to December 2015. Neither systemic nor ocular complications were seen in all studied patients during the study period. Absence of complications in this study was also noted in similar previous studies.^[20,21] On the other hand, a large uncontrolled clinical study included 4303 patients has reported cardiovascular and cerebrovascular complications in 18 patients, and bacterial endophthmilitis in 7 patients.^[15] In that study, however, the used inclusion and exclusion criteria were not so coherent that the potential risk of complications would not be prevented. In our and other similar studies, however, many patients with suggested risk of developing such complications were excluded, and all injection procedures were done under complete aseptic conditions.

The study findings revealed significant reduction in mean central macular thickness from 425.2 to 365.5 micrometers. Similar significant reduction in macular thickness was also

reported in many studies. In one study, the central retinal thickness showed a considerable reduction from 498.9 at baseline to 370.4 micrometers at one month follow-up.^[22] In another study carried out by Arevalo *et al.*^[21] The mean central macular thickness by OCT, among the studied 88 patients, was found to decrease from 387.0 at baseline to 275.7 at end of 16 weeks follow-up period. The mean decreases in central macular thickness after single intravitreal injection of 1.25mg of bevacizumab noticed after one month was about 61.4 ± 33.2 micrometers.^[22] In our study, the mean difference was very like that reported in the previous study. It was 59.7 ± 32.5 .

In our study, stratified analysis by patients' characteristics were also performed and revealed significant reduction in the mean macular thickness after bevacizumab injection among patients less than 60 years, and male patients, and those with best corrected visual acuity at baseline ≥ 0.1 . These findings coincide with that reported in many previous studies^[16-18], and confirm the accumulating literature that young age, male gender and best corrected visual acuity at baseline as the most important prognostic factors after intravitreal injection of bevacizumab. Stratified analysis by reason of injection showed statistically significant reduction in the mean macular thickness among patients presented with DME, Macular edema secondary to BRVO, Neovascular glaucoma and among those patients presented with Macular edema secondary to CRVO. These findings were also reported in previous similar studies.^[17,18]

The study findings found that 41 eyes showed $\geq 10\%$, and 18 eyes showed $< 10\%$ decrease in macular thickness. Ateeq *et al.*^[20] in their study included 54 patients who were submitted to intravitreal injection of bevacizumab, 43 Eyes (79.6%) showed $\geq 10\%$ decrease in macular thickness from pre-injection thickness, 10 Eyes (18.5%) showed $< 10\%$ decrease macular thickness post operatively after one month.

Macular thickness reduction, three months after bevacizumab, was analyzed in the present study by patients' diagnosis. More than ten percent reduction in macular thickness was found in 23 (38.9%) out of 35 DME patients, 5 (8.4%) out of 9 patients with PDR, and 5 (8.4%) out of 5 patients presented with PDR and VR, and 4 (6.7%) out of 4 patients with DME and PDR. The use of bevacizumab with success in treatment of diabetic macular edema is very beneficial for diabetic patients. DME is one of the major complications, leading to irreversible visual loss among diabetic patients, and up to 10% of diabetics develop it during their lifetime.^[23] According to the Early Treatment Diabetic Retinopathy Study (ETDRS),

focal laser photocoagulation reduces the rate of visual loss by 50% among these patients.^[24]

On the other hand, it is impossible to use complete macular grid laser in patients having media opacity like cataract, so there is a great need for an alternative or adjunctive treatment.^[20] The usefulness of intravitreal injection of bevacizumab in these patients may help to reduce visual loss in patients with DME.

The biological plausibility of the effectiveness of intravitreal injection of bevacizumab in treatment of these patients could be explained by the etiologic factor implicated in development of macular edema. Vascular endothelial growth factor (VEGF), discovered in 1989, secreted by normal retinal pigment epithelial cells as result of hypoxia is known to be significantly elevated in diabetic eyes^[25,26], particularly those eyes with proliferative diabetic retinopathy.^[27] It is also observed that eyes with heavy macular leakage to have significantly higher VEGF concentration compared to eyes with less leakage.^[28] Therefore, anti-VEGF treatments can be considered as an adjunctive treatment for DME.^[29] Bevacizumab is a monoclonal antibody that binds to all kinds of VEGF and thus inhibiting its adverse effects.^[1]

The second studied outcome parameter in this study was the visual acuity. At baseline, there were 38 eyes (64.4%) with best corrected visual acuity of ≥ 0.1 Decimal. Three months after intravitreal injection of bevacizumab, a significant improvement in patients' best corrected visual acuity by about 14% was detected in the studied eyes. Moreover, paired analyses have revealed that 9 (43%) out of studied 21 patients with baseline visual acuity < 0.1 Decimal were corrected, and only one eye (7.7%) of 38 eyes with baseline visual acuity ≥ 0.1 Decimal was deteriorated. Costa et al.^[30] have demonstrated significant dose-response changes in best corrected visual acuity at 3 months follow-up in their prospective, nonrandomized open-label study of 45 patients with ME and subfoveal CNV. The vision improved by +0.3 ETDRS line after a dose of 1.0 mg, by +0.6 line after 1.5 mg, and by +1.0 line after 2.0 mg of intravitreal injection of bevacizumab. In a case report study, a 69 years old woman with DME underwent an intravitreal injection of bevacizumab at a dose of 2.5 mg in her eye. There has been an improvement of her visual acuity to 20/400 one month, and 20/200 four months after injection.^[31] Another recent study has reported a highly significant improvement of visual acuity after intravitreal bevacizumab injection. The mean baseline acuity was 20/494 and the mean acuity at three months following injection was 20/295.^[32] Over the years, many studies have documented the highly effective role of anti-VEGF treatment in preserving visual acuity in most eyes with proliferative neovascularization and age-related macular denegation.^[33-35]

In conclusion, the study confirmed the usefulness and short-term efficacy of intravitreal injection of bevacizumab in patients with macular edema of different causes, particularly those with diabetes. Intravitreal bevacizumab injection was found to significantly reduce the central macular edema and to improve the visual acuity of the studied eyes. Selection of patients submitted to this procedure is mandatory to obtain these required positive results. Apart from its efficacy, intravitreal injection of bevacizumab has also appeared to be relatively safe in the short-term with no cases of systemic or ocular complications have been reported in this case series follow-up study.

According to our knowledge, this study is the first to assess short-term outcome of intravitreal injection bevacizumab injection in Madinah medical centers. Moreover, and unlike other similar studies, the present study has stratified all analyses concerning the studied outcome parameters by patients' clinical and demographic characteristics. Though the above mentioned positive points, the nonrandomized nature of this study prevents any estimation of the long-term safety and/or efficacy of the studied procedure. However, the study findings are quite promising and suggest the need for further investigations with larger multicenter randomized studies.

COMPETING INTERESTS

The authors declare that there have no competing interests regarding the publication of this manuscript.

LIMITATIONS

The study was unable to score one-month OCT and there wasn't further follow up after three months. The OCT results were limited in vitreous hemorrhage.

CONCLUSION

The study confirms the accumulating evidence of the usefulness and short-term efficacy of intravitreal injection of bevacizumab.

FURTHER WORK

The study suggests the need for further investigations with larger multicenter randomized studies and the need for increasing awareness about the importance of diabetes control and its impact in our region.

ACKNOWLEDGMENT

The authors would like to thank all patients participated in this study. The authors also acknowledge the help of all staff at eye center at Ohoud hospital especially Dr. Maram Alali.

REFERENCES

1. Ferrara N, Hillan KJ, Gerber HP, Novotny W. Discovery and development of bevacizumab, an anti-VEGF antibody for treating cancer. *Nature Reviews Drug Discovery*, 2004; 3(5): 391-400.
2. Aiello LP, Avery RL, Arrigg PG, Keyt BA, Jampel HD, Shah ST, et al. Vascular endothelial growth factor in ocular fluid of patients with diabetic retinopathy and other retinal disorders. *N Engl J Med.*, 1994; 331: 1480-1485.
3. Arevalo JF, Sanchez JG, Wu L et al. Primary intravitreal bevacizumab for diffuse diabetic macular edema. The Pan-American Collaborative Retina Study Group at 24 months. *Ophthalmology*, 2009; 116(8): 1488-1497.
4. Bressler NM, Altaweel M. Changes in retinal neovascularization after pegaptanib (Macugen) therapy in diabetic individuals. *Ophthalmology*, 2006; 113(1): 23-28.
5. Spaide RF, Fisher YL. Intravitreal bevacizumab (Bevacizumab) treatment of proliferative diabetic retinopathy complicated by vitreous hemorrhage. *Retina*, 2006; 26(4): 275-278.
6. Arevalo JF, Wu L, Sanchez JG et al. Intravitreal bevacizumab (Bevacizumab) for proliferative diabetic retinopathy: 6-months follow-up. *Eye*, 2009; 23(1): 117-123.
7. Michels S, Rosenfeld PJ, Puliafito CA, Marcus EN, Venkatraman AS. Systemic bevacizumab (Bevacizumab) therapy for neovascular age-related macular degeneration: twelve-week results of an uncontrolled open-label clinical study. *Ophthalmology*, 2005; 112(6): 1035-1047.
8. Avery RL, Pieramici DJ, Rabena MD, Castellarin AA, Nasir MA, Giust MJ. bevacizumab (Bevacizumab) for neovascular age-related macular degeneration. *Ophthalmology*, 2006; 113(3): 363-372.e5.
9. Avery RL, Pearlman J, Pieramici DJ et al. Intravitreal bevacizumab (Bevacizumab) in the treatment of proliferative diabetic retinopathy. *Ophthalmology*, 2006; 113(10): 1695-1705.e6.
10. Iturralde D, Spaide RF, Meyerle CB et al. Intravitreal bevacizumab (Bevacizumab) treatment of macular edema in central retinal vein occlusion: a short-term study. *Retina*, 2006; 26(3): 279-284.

11. Mason JO, Nixon PA, White MF. Intravitreal injection of bevacizumab (Bevacizumab) as adjunctive treatment of proliferative diabetic retinopathy. *American Journal of Ophthalmology*, 2006; 142(4): 685-688.
12. Wu L, Evans T, Saravia M, Schlaen A, Couto C. Intravitreal bevacizumab for choroidal neovascularization secondary to Vogt-Koyanagi-Harada syndrome.
13. Manzano RPA, Peyman GA, Khan P, Kivilcim M. Testing intravitreal toxicity of bevacizumab (Bevacizumab). *Retina*, 2006; 26(3): 257-261.
14. Micieli JA, Micieli A, Smith AF. Identifying systemic safety signals following intravitreal bevacizumab: Systematic review of the literature and the Canadian Adverse Drug Reaction Database. *Can J Ophthalmol*, 2010; 45(3): 231–238.
15. Wu L, Martínez-Castellanos MA, Quiroz-Mercado H et al. Twelve-month safety of intravitreal injections of bevacizumab (Bevacizumab®): results of the pan-american collaborative retina study group (PACORES). *Graefes Archive for Clinical and Experimental Ophthalmology*, 2008; 246(1): 81-87.
16. Mason JO, Albert MA, Jr, Mays A, et al. Regression of neovascular iris vessels by intravitreal injection of bevacizumab. *Retina*, 2006; 26.
17. Paula JS, Jorge R, Costa RA, et al. Short-term results of intravitreal bevacizumab (Bevacizumab) on anterior segment neovascularisation in neovascular glaucoma. *Acta Ophthalmol Scand*, 2006; 84: 556-557.
18. Vatavuk Z, Bencic G, Mandic Z. Intravitreal bevacizumab for neovascular glaucoma following central retinal artery occlusion. *Eur J Ophthalmol*, 2007; 17: 269-271.
19. SAS Institute Inc. (1999). Propriety software release 8.2. SAS Institute Inc, Cary, NC, 1999.
20. Ateeq A, Tahir MA, Cheema A, Dahri A, Tareen S. Intravitreal injection of Bevacizumab in diabetic macular edema, 2014; 30(6): 1383-1387.
21. Arevalo JF, Wu L, Sanchez JG, Maia M, Saravia MJ, Fernandez CF, et al. Intravitreal bevacizumab (Bevacizumab) for proliferative diabetic retinopathy: 6-months follow-up. *Eye*, 2009; 23: 117-123.
22. Haritoglou C, Kook D, Neubauer A, Wolf A, Priglinger S, Strauss R, et al. Intravitreal bevacizumab (Bevacizumab) therapy for persistent diffuse diabetic macular edema. *Retina*, 2006; 26: 999-1005.
23. Ferris FL, 3rd, Patz A. Macular edema: a complication of diabetic retinopathy. *Surv Ophthalmol*, 1984; 28: 452-461.

24. Early Treatment Diabetic Retinopathy Study Research Group. Photocoagulation for diabetic macular edema Early Treatment Diabetic Retinopathy Study Report Number 1. *Arch Ophthalmol*, 1985; 103: 1796-1806.
25. Qaum T, Xu Q, Jousseaume AM, Clemens MW, Qin W, Miyamoto K, et al. VEGF-initiated blood-retinal barrier breakdown in early diabetes. *Invest Ophthalmol Vis Sci.*, 2001; 42(10): 2408-2413.
26. Aiello LP, Avery RL, Arrigg PG, Keyt BA, Jampel HD, Shah ST, et al. Vascular endothelial growth factor in ocular fluid of patients with diabetic retinopathy and other retinal disorders. *N Engl J Med.*, 1994; 331(22): 1480-1487.
27. Adamis AP, Miller JW, Bernal MT, D'Amico DJ, Folkman J, Yeo TK, Yeo KT. Increased vascular endothelial growth factor levels in the vitreous of eyes with proliferative diabetic retinopathy. *Am J Ophthalmol*, 1994; 118(4): 445-450.
28. Funatsu H, Yamashita H, Noma H, Mimura T, Yamashita T, Hori S. Increased levels of vascular endothelial growth factor and interleukin-6 in the aqueous humor of diabetics with macular edema. *Am J Ophthalmol*, 2002; 133(1): 70-77.
29. Funatsu H, Yamashita H, Ikeda T, Nakanishi Y, Kitano S, Hori S. Angiotensin II and vascular endothelial growth factor in the vitreous fluid of patients with diabetic macular edema and other retinal disorders. *Am J Ophthalmol*, 2002; 133(4): 537-543.
30. Costa RA, Jorge R, Calucci D, et al. Intravitreal bevacizumab for choroidal neovascularisation caused by AMD (IBeNA Study): results of a phase 1 dose-escalation study. *Invest Ophthalmol Vis Sci.*, 2006; 47: 4569-4578.
31. Arevalo JF, Sanchez JG, Lasave AF, et al. Intravitreal Bevacizumab (Bevacizumab) for Diabetic Retinopathy: The 2010 GLADAOF Lecture. *Journal of Ophthalmology*, 2011; 2011: 1-13.
32. Kumar A, Sinha S. Intravitreal bevacizumab (Bevacizumab) treatment of diffuse diabetic macular edema in an Indian population. *Indian Journal of Ophthalmology*, 2007; 55(6): 451-455.
33. Martin DF, Maguire MG, Ying GS, Grunwald JE, Fine SL, Jaffe GJ. CATT Research Group. Ranibizumab and bevacizumab for neovascular age-related macular degeneration. *N Engl J Med.*, 2011; 364(20): 1897-1908.
34. Martin DF, Maguire MG, Fine SL, et al. Comparison of Age-related Macular Degeneration Treatments Trials (CATT) Research Group. Ranibizumab and bevacizumab for treatment of neovascular age-related macular degeneration: two-year results. *Ophthalmology*, 2012; 119(7): 1388-1398.

35. Chakravarthy U, Harding SP, Rogers CA, et al. IVAN Study Investigators. Ranibizumab versus bevacizumab to treat neovascular age-related macular degeneration: one-year findings from the IVAN randomized trial. *Ophthalmology*, 2012; 119(7): 1399-1411.