

PROTECTIVE ROLE OF FOLIC ACID AND VITAMIN B12 ON SEMEN QUALITY, TESTOSTERONE LEVEL AND HISTOLOGICAL FEATURE IN NICOTINE INTOXICATED MALE RATS.

¹Dibyendu Ray*, ²Amalendu Samanta, ³Ankita Bhattacharya, ⁴Amal Chandra Mondal, ⁵Sandip Mukherjee

¹Assistant Professor and Haed, Dept Physiology (UG and PG), Serampore College, 1 under Calcutta University.

²Serampore College.

³Serampore College.

⁴Associate Professor in Cellular and Molecular Neurobiology Jawaharlal Nehru University, New Delhi.

⁵Serampore College.

Article Received on
27 March 2018,

Revised on 16 April 2018,
Accepted on 07 May 2018

DOI: 10.20959/wjpr201810-12315

***Corresponding Author**

Dibyendu Ray

India.

ABSTRACT

Nicotine (NIC) adversely affects male reproductive system, semen quality and fertility. The present study elucidated the protective role folic acid with or without vitamin B12 in adult wister male rats. Rats were treated with nicotine (administerated by intraperitoneal injection of nicotine 3mg/kg body weight /day with supplementation of folic acid alone (36µg/kg bw/day) or in combination with vitamin B12(0.63µg/kg/day) for 21 days. The NIC-exposed rats showed

significant reduction in testicular weight, epididymal sperm count, motility, serum level of FSH, LH and testosterone with damaged histoarcitecture of testes probably by affecting pituitary gonadotrophins and/or modulating antioxidant status. The above mentioned parameters were restored to near normal level by supplementation of folic acid and vitamin B12. In conclusion, folic acid and vitamin B12 may be used as possible reproductive Protectants after additional study molecular and clinical trial level.

KEY WORDS: Nicotine, Folic acid, Vitamin B12, Gonadotrophins, Testosterone, Sperm.

INTRODUCTION

Tobacco use among youth is a major problem in the world and use of it kills millions of people worldwide. Despite anti-smoking campaign, cigarette smoking is very common with highest prevalence observed in in young.^[1] The number of tobacco smokers in the population in the 3rd world will increase form 4.5billion to 7.5 billion by 2025.

Cigarette smoke is a complex mixture of 400 toxic chemicals including nicotine, carbon monoxide, and several recognized carcinogens and mutagens. These toxicants are absorbed through the pulmonary vasculature and transported via the bloodstream causing cytotoxicity, genotoxicity, and tumorigenicity throughout the body.^[2-3] Nicotine is metabolized to cotinine primarily by the liver, and to a lesser extent, the lung and kidney.

Infertility is now become a common reproductive disorder that affects approximately one of six couples worldwide.^[4] It has been reported that tobacco use is associated with decreased fertility in both male and female and also has negative impact on on the clinical out come of ART.^[5]

Ample of studies reported that nicotine(NIC), an active and addictive alkaloid compound of cigarette and tobacco products, can cause detrimental effects on male reproductive system and on fertility have been reported^[6] However, the mechanism by which NIC cause male infertility is poorly understood. It was previously demonstrated that both nicotine and and its metabolite cotinine, adversely affected spermatogenesis, sperm count and oral adminsteration of NIC in rat led to degeneration of testes, alteration of serum testosterone level.

Tobacco consumption has recently been documented to act as an endocrine disruptor on the male hormone profile, specifically on LH, testosterone, and prolactin levels.^[7] Several studies reported that NIC decreases testicular enzymes along with plasma testosterone and sperm count in experimental animal. The synthesis and release of andogens depend on pituitary gonadrophins LH and FSH via hypoyhalomo-pituitary-gonadal axis.^[8] LH trophic to Leydig cells and secrete testosterone which in turn affects spermatogenesis, male sex charecteristics. FSH regulates the function of Sertoli cells and promote spermatogenesis.^[9]

The nutritional management has been shown advantages in Nic induced toxicity. Some of our previous studies explored that supplementation of folic acid(FA) and vit B12 reverse the NIC induced toxicity on pancreas tissues.^[10] Mukherjee et al also reported that FA and vit B12

also effective in Arsenic induced pancreas toxicity^[11] Dietary factors such as FA vit B12 are involve in one carbon metabolism, DNA methylation, which in turn involve carcinogen.

Though several vitamins and micronutrients have been tested, the literature on FA and vitamin B12 is inadequate. Further smokers have low folic acid and vitamin B12 and high homocystine level which increases their risk on cardiovascular.^[12] In humans, vitamin B12 is transferred from blood to male reproductive organs and exerts positive effects on sperm parameters (e.g sperm count, motility sperm DNA).^[13] The present study was, therefore, designed to investigate if nicotine induced infertility is associated with alteration pituitary-gonadal hormones and its amelioration by FA and vitamin B12. Besides, this study also conducted to provide preliminary data on the protective and beneficial effects of FA and vitB12 on this male gonadal organ.

MATERIALS AND METHODS

Experimental animals

The present was performed on twenty four adult Wister male rats of similar age with an average weight of 110 ± 10 g. All animal experiments were performed according to the ethical guidelines suggested by the Institutional Animal Ethics Committee (IAEC) of Serampore College, West Bengal, India. The animals were maintained in an environmentally controlled animal house and in a 12hour light/dark schedule with free access to water supply. All rats were acclimatized for about two weeks prior to the beginning of the study.

Nicotine

Nicotine (NIC) was procured from Sigma-Aldrich (USA) Working nicotine prepared by highest body weight of rat, i.e. 3mg/kg body weight. The dose and administration route were selected according to previous studies.^[11]

Experimental Protocol

Twenty four rats were randomly divided into 4 groups (n=6) as follows Group I: Control untreated, received 1ml physiological saline Group II: Nicotine (administrated by intraperitoneal injection of nicotine 3mg/kg body weight Group III: rats were supplemented with folic acid by gavage at a dose of $36 \mu\text{g}/\text{kg}$ bw, **orally for 21 days.** Group IV: Treated with nicotine (i.p3mg/kg body weight) plus $36 \mu\text{g}/\text{kg}$ folic acid and $0.63 \mu\text{g}/\text{kg}$ vitamin B12 orally. Treatments were carried for 21 days and the dose and administration route were selected according to previous studies.^[10,-11]

BODY AND REPRODUCTIVE ORGAN WEIGHT

Body weights were recorded weekly during experimental period. At end of the experiment, the animals were sacrificed by decapitation under ether anaesthesia. Body weights were recorded before sacrifice and male reproductive organs quickly removed and weighted

PLASMA PREPARATION and HORMONAL ASSAY (DETERMINATION OF LH, FSH, AND TESTOSTERONE)

After the treatment periods were over (21 days), the animals of all groups were anaesthetized and sacrificed by cervical dislocation, which is one of the recommended physical methods of euthanasia by IAEC. Blood sample was drawn from heart and the samples were then spun at 2,500 rpm for 10 minutes in a table top centrifuge. The serum samples obtained were analyzed to determine the concentration of testosterone, LH, FSH by using the accubind ELISA kit obtained from Monobind, USA. All samples were assayed in duplicate. To avoid interassay variation, all samples were run at one time. In order to minimize the effect of diurnal fluctuation, all samples were obtained in baseline conditions between 8:00 A.M. and 9:30 A.M.

SPERM COUNT AND SPERM MOTILITY

After sacrifice the animals, caudal epididymis part of animals was removed and placed in small clean Petridis containing 1ml of phosphate buffer saline pH7.4. the caudal part was cut by sterilised blade into three pieces and squeezed gently by a fine forceps to release the sperm into PBS, then sperm were count by Neubauer Haemocytometer Chamber. Sperm suspension was placed on both sides of chamber and no. of sperm in squares of chamber was counted under the microscope at 100x magnification (Barneveld et al., 1977). Sperm count and motility was performed four times for each sample in accordance with WHO Laboratory Manual.^[15]

Testicular Histology

The testes of all the rats were fixed in 10% formalin, dehydrated stepwise in graded ethanol, cleared in xylene and then embedded in paraffin wax. A section of 5µm thick paraffin section of each testicular tissue was stained with hematoxylin and eosin, followed by examination under a light microscope at 200 magnification and micrographs taken.^[16]

STATISTICAL ANALYSIS

The obtained data were expressed as mean \pm SE. Kruskal – Wallis nonparametric one way analysis of variance (ANOVA). Test was performed to establish whether or not scores of different groups differed significantly and to test intergroup significant difference, Mann-Whitney U multiple comparison tests was performed by using Stat Direct Software (UK). Differences were considered significant at (P<0.05).

RESULTS

1. Reproductive organ weights

As shown in table (1) injecting adult male rats with NIC caused statistically significant reduction in the weight of both right and left testis. However, folic acid alone or co-administration with vitamin B12 showed significant increase in weight and restored the weight of testes.

Table 1: Testicular Weight, Sperm Count and Motility.

Groups	Weight of Testis (per 100gm body weight)	Motility (%)	Count (10 ⁶ /ml)
Control	0.970	73	50.396
Nicotine(NIC)	0.845	44.45	17.644
NIC+Folic acid	0.900	67.0	31.751
Nic+folic acid +Vit B12	0.945	70.8	48.786

2. Hormonal analysis (Gonadotrophic Hormones & male reproductive hormone)

Testosterone

The mean serum testosterone level of rats that received 0.3 mg/kg body weight (B.W.) of nicotine for 21days was significantly decreased (P < 0.05) when compared with the control group and it was not ameliorated by folic acid alone. Cotreatment of folic acid with vitamin B12to nicotine-treated rats significantly restricted the decrease of the testosteronelevel as shown figure 1.

Luteinizing hormone

The results showed that there was a significant decrease (P < 0.05) in the mean serum LH level of rats that received 3.0 mg/kg B.W. nicotine daily for three weeks when compared with their control. However, supplementation of folic acid with vitamin B12 in nicotine treated rats significantly prevented this reduction (Figure 2).

Follicle stimulating hormone

The mean FSH level of rats that received 3.0 mg/kg BW nicotine daily for three weeks was significantly decreased ($P < 0.05$) when compared with the control group. Supplementation of folic acid with vitamin B12 in nicotine treated rats significantly increased the mean serum FSH level when compared with their control counterpart as shown in figure 3.

3. Histology

Eosin-hematoxyline stained testicular tissue section revealed that nicotine led to necrosis and degeneration of seminiferous tubule with significant increase in lumen diameter. Folic acid with vitamin B12 coadministration in NIC –treated animal showed partial but significant protection, which was evident from histoarchitecture,(figure 4)

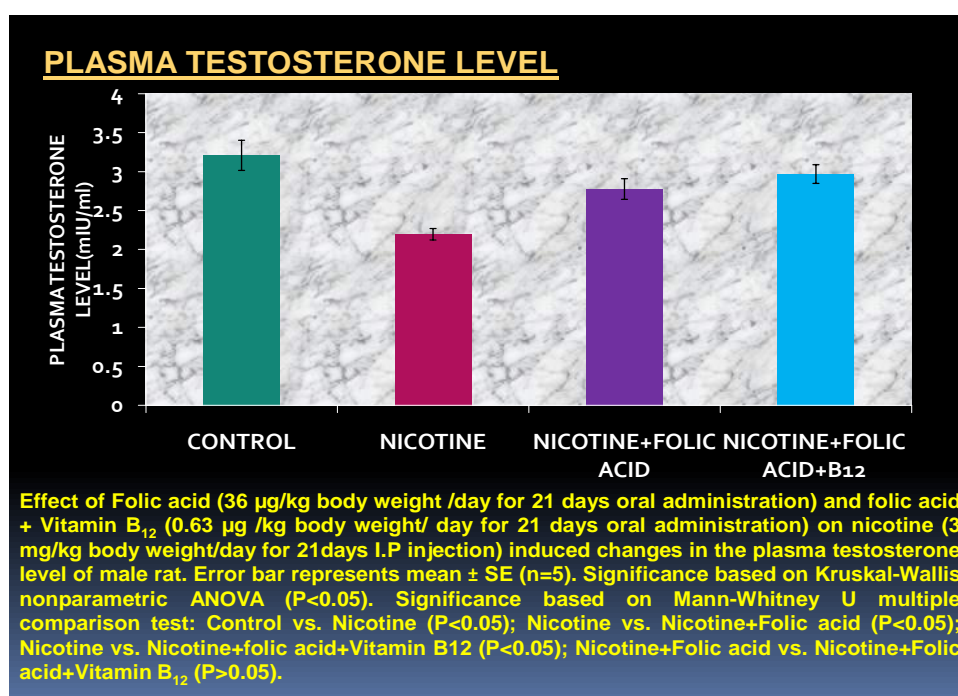


Figure 1.

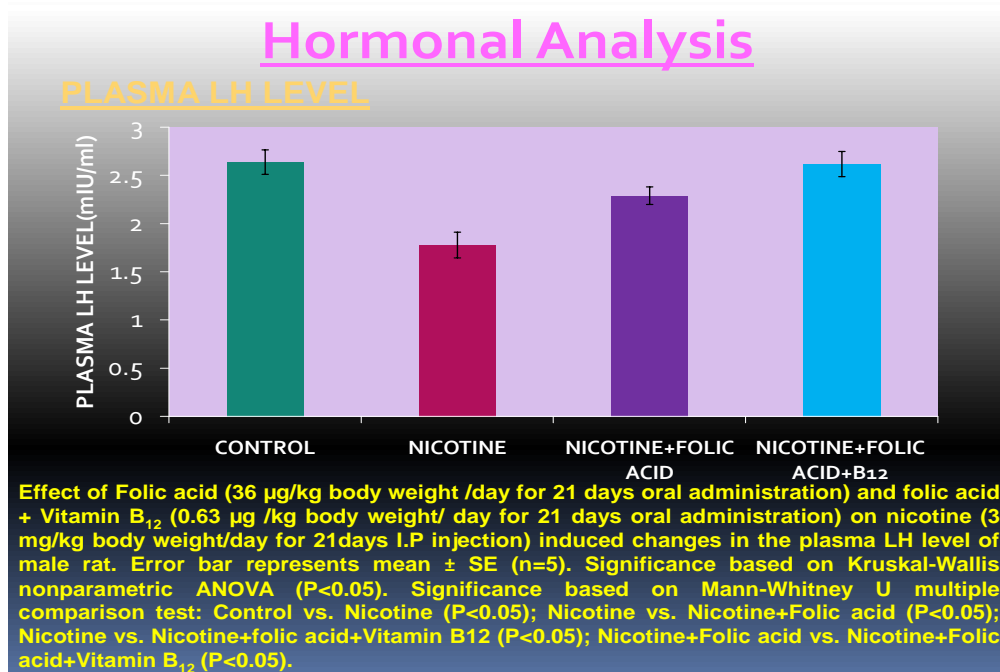


Figure 2.

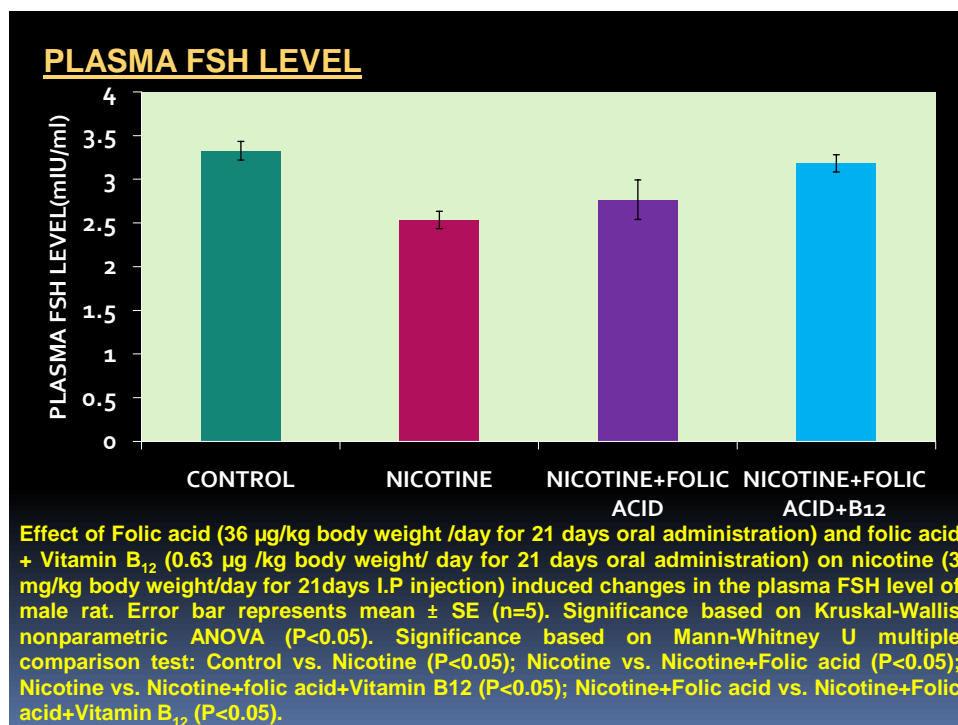


Figure 3.

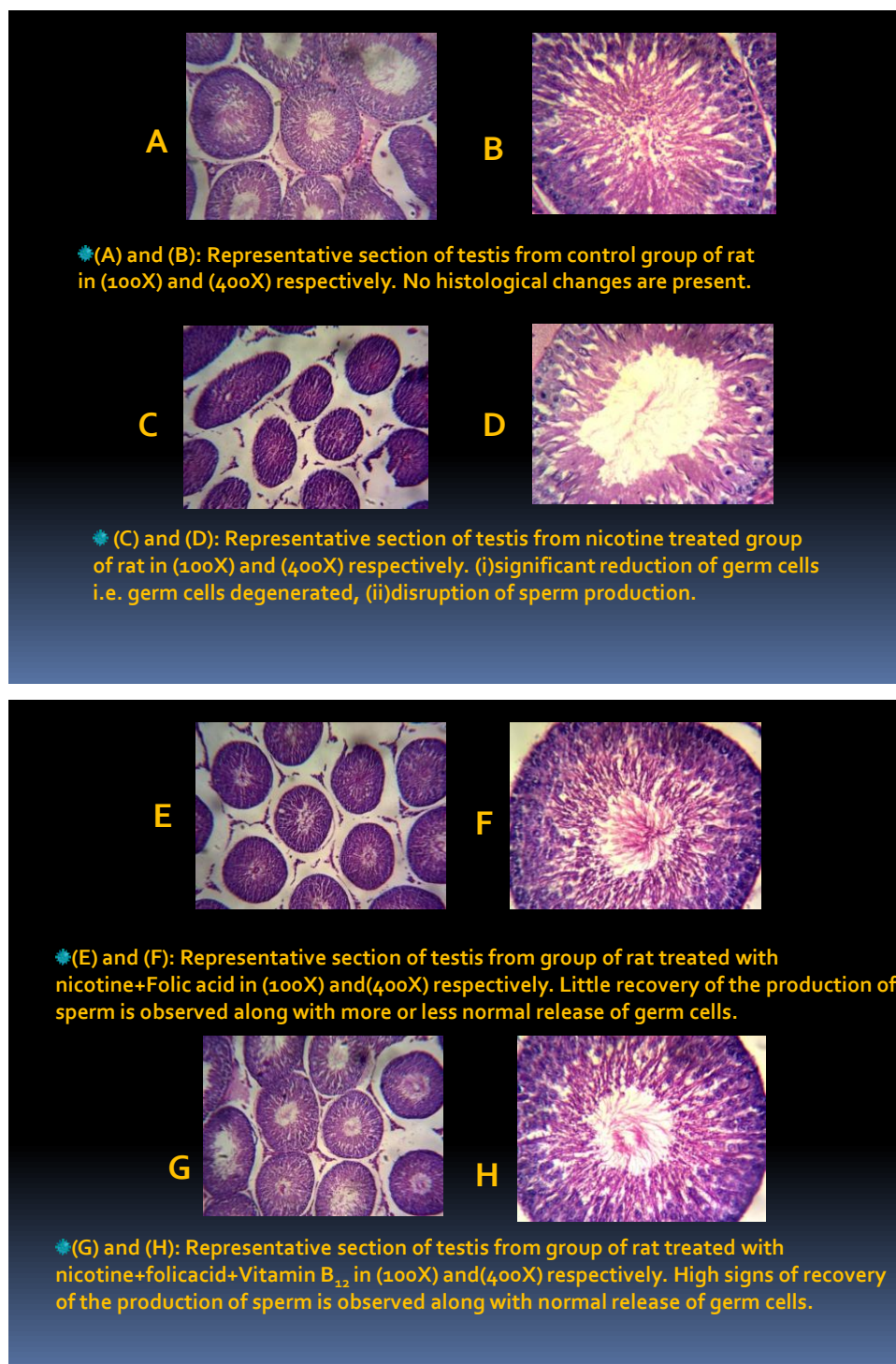


Figure 4.

DISCUSSION

Pituitary-testicular axis is immensely important in regulation of male reproductive functions. Testosterone, being an important androgen plays a pivotal role in several aspects of sexual maturation, behavior, spermatogenesis, differentiation, and maintenance of accessory sex organs in males.^[17] The synthesis and release of androgens is dependent on the pituitary

gonadotrophins, which are FSH and LH. Both FSH and LH are essential for testicular function and spermatogenesis. LH is the main tropic regulator of Leydig cell function without which androgen production is not possible.^[9]

LH-The observed decrease in serum testosterone level of rats treated with the nicotine is associated with a decrease in LH, thus suggesting that the etiology is not associated with a disorder in the pituitary but rather a testicular dysfunction, which is indicated when low serum testosterone levels are accompanied by high levels of serum LH. This might have been caused by the disruption of testicular cytoarchitecture by nicotine also observed in previous studies; consequently, adversely affected Leydig cell number and functioning leading to decrease serum testosterone level since Leydig cells secrete testosterone.

The serum level of FSH of the rats treated with 3.0 mg/kg B.W. of nicotine was significantly decreased when compared with their control counterparts. Decrease in FSH observed with nicotine treatment could be due to increase release of inhibin by the sertoli cell thus inhibiting the release of FSH from the anterior pituitary and possibly also a negative effect on the hypothalamus to inhibit the secretion of GnRH. The decrease observed in this study is in agreement with earlier study that also reported a decrease in FSH with nicotine administration.^[18] Primary testicular failure and hypothalamic causes have been reported to likely result in primary male infertility due to sexually transmitted diseases, trauma, environmental factors and social habits like smoking and consuming alcohol. Meanwhile, the results of this study showed significant reduction in FSH, LH and testosterone in rats that were exposed to nicotine, although,^[19] reported high plasma FSH level in male smokers. The possibility of the low levels of plasma FSH and LH concentration following nicotine exposure has been reported to be probably due to elevation of glucocorticoid and corticosterone secretion from adrenal gland^[20] glucocorticoid may suppress the sensitivity of the gonadotroph cells to gonadotropin-releasing hormone and, therefore, may prevent gonadotropin secretion.^[21] Inhibition of FSH and LH by nicotine may also be as a result of its negative effect on central nervous system that can inhibit the neural stimulus essential for the release of pituitary gonadotrophins^[22] which lead to a lack of pituitary gonadotrophins essential for initiating and completing spermatogenesis and steroidogenesis in the testis.

This decrease in epididymal sperm count observed in the previous study could be connected to the decrease in the serum testosterone and FSH level observed in this present study. Testosterone is associated with FSH, which acts on the seminiferous tubules to initiate and

maintain spermatogenesis. Sexual maturation in male rat is related with an increase in FSH secretion since FSH binds within the seminiferous tubules to facilitate spermatogenesis.^[13]

The structural architecture of the testis was intact with a normal spermatogenic process in the control rats of this study, while there was a destruction of both fibrous connective tissue surrounding the seminiferous tubule and spermatogenesis process in nicotine exposed rats. This may account for the reduction in sperm motility, counts and viability and plasma testosterone observed in this study. The disarray in testicular histology observed was gradually reorganized in folic acid group.

In this study, supplementation of folic acid with or without vitamin B12 to nicotine treated rats was found to be successful in reversing the nicotine induced impairment of hormonal milieu of reproduction and significantly improved the plasma level of FSH, LH and testosterone. The observed elevation in FSH and LH by folic acid and Vitamin B12 supplement in rats exposed to nicotine may be related to the fact that these vitamins, like ascorbic acid, can be a vitaminergic transmitter that activates the release of LH and FSH from the anterior pituitary gland (Karanth et al., 2001).^[23]

Although, the antioxidant property of folic acid was not measured in the present investigation, several lines of evidences suggest that folic acid and vitamin B12 act as antioxidant.^[11,24,25] Further, Anti-oxidant activity was reported to be more efficient when antioxidants were used in combination.^[26] The ameliorating action of folic acid and vitamin B12 in elevating FSH, LH and testosterone in nicotine treated rats may thus be attributed to their anti-oxidant property which may prevent the depressive effects of nicotine on the hypothalamus that secrete gonadotrophin which in turn control pituitary gonadotrophins.

It has also been proven that nicotine induced ROS generation in testicular tissues by increased generation of H₂O₂ and OH⁻, which led to oxidative stress.^[27] This oxidative stress causes tissue damage in the testes, lipidperoxidation and with loss of sperm. In the present study, testosterone level, testicular tissues and semen quality were significantly improved by supplementation of folic acid with or without vitamin B12.

CONCLUSION

In conclusion, folic acid alone or in combination with vitamin B12 prevented nicotine induced disturbances in pituitary –gonadal axis, testicular toxicity and may be used as possible reproductive protectants after additional study molecular and clinical trial level.

REFERENCES

1. United Nation. World population prospects 1990. New York 226-231.
2. Bernhard D, Rossmann A, Wick G. Metals in cigarette smoke. *IUBMB Life*, 2005; 57: 805-8093.
3. Kumar PS, Matthews CR, Joshi V, de Jager M, Aspiras M. Tobacco smoking affects bacterial acquisition and colonization in oral biofilms. *Infect Immun*, 2011; 79: 4730-4738.
4. Brugh VM, Lipshultz LI. Male factor infertility: evaluation and management. *Med Clin North Am*, 2004; 88: 367-385.
5. Practice committee of American Society for Reproductive medicine. Smoking and infertility. *Fertil Steril*, 2008; 90: s254-s259.
6. Gour DS, et al. Alcohol intake and cigarette smoking; impact of two major lifesyyle factor on male fertility Indian j payhol microbial, 2010; 53: 35-40.
7. Blanco-Munoz J, Lacasaña M, Aguilar-Garduno C. Effect of current tobacco on the male reproductive hormone profile. *Sci Total Environ*, 2012; 426: 100-5.
8. Ojeda SR, Urbanski HF. Puberty in rat. In: Knobil E, Neil JE, editors. *The Physiology of Reproduction*. 2nd ed. New York II: Raven Press, 1994; 363-409.
9. Barret KE, Barmen SM, Baitano S& Brook HL 2011. *Ganong's review of Medical Physiology*. 23rd edition, Tata McGrew Hill education private Limited, 404.
10. Bhattacharjee A, Prasad SK, Maji BM, Mukherjee et al. protective efficacy of folic acid and vitamin B12 against nicotine-induced toxicity in pancreatic islets of rats. *Interdiscip Toxicol*, 2015; 8(2): 103.
11. Mukherjee S, Das D, Mukherjee M, Das A and Mitra C. Synergistic effect of folic acid and vitamin B12 in ameliorating arsenic induced oxidative damage in pancreatic tissue of rat. *J. Nutr. Biochem*, 2006; 17: 319-327.
12. Mansoor MA, Kristensen O, Hetland O and Osland A. low concentration of folate in serum and in erythrocyte of smokers; methionine loading decreases folate concentration in serum of smokers and nonsmokers. *Clin. Chem*, 1997; 43: 2192-2194.
13. Watson, AA. Seminal vitmin B12 and sterility. *Lancet*, 1962; 2: 644.

14. Chattopadhyay K, Chattopadhyay BD. Effect of nicotine on lipid peroxidation and antioxidant enzymes in female rats. *Indian J. Med. Res.*, 127: 571-576.
15. World Health Organization, WHO Laboratory Manual for Examination of Human Semen. The Press Syndicate of the University of Cambridge, UK, 4th edition, 1999.
16. Bancroft JD, Stevens, A. Theories and practice of histological technique 2002, 4th edition, Queens Medical Centre, NHS Trust.
17. Ojeda SR, Urbanski HF. Puberty in rat. In: Knobil E, Neil JE, editors. *The Physiology of Reproduction*. 2nd ed. New York II: Raven Press, 1994; 363-409.
18. Andersen AN, Semczuk M, Tabor A. Prolactin and pituitary gonadal function in cigarette smoking infertile patients. *Andrologia*, 1984; 16: 391-396.
19. Zavos, P.M Cigarette smoking and human reproduction: effects on female and male fecundity. *Infertility*, 1989; 12: 35-46.
20. Jana, K, Samanta, PK, DE, DK. Nicotine diminishes testicular gametogenesis, steroidogenesis, and steroidogenic acute regulatory protein expression in adult albino rats: possible influences on pituitary gonadotrophin and alteration of testicular antioxidant status; *Toxicological Sciences*, 116: 647-659.
21. Kamel, FA and Kubajak, CL, modulation of gonadotrophin secretion by corticosterone interaction with gonadal steroids and mechanism of action. *Endocrinol*, 121: 561-565.
22. Reddy, A, Sood, A, Rust PF, Busby, JE and Mathur, RS. The effect of nicotine on in-vitro sperm motion characteristics. *J. of Assisted Reprod. and Genetics*, 1995; 12: 217-223.
23. Karanath S, Yu WE, Walczeska A, Mastronardi CA & McCann M. Ascorbic acid stimulates gonadotrophin release by autocrine action means of NO, *Proc Natl Aca Sci*, 98: 11783-11788.
24. Chattopadhyay S, Deb B, and Maiti S. Hepatoprotective effect of vitamin B12 and folic acid in arsenic intoxicated rats. *Drug and Chemical Toxicology*, 2012; 35(1): 81-88.
25. Hu, JH, Tian WQ, Zhao, XL, Li, QW. The cytoprotective effects of vitamin B12 supplementation on bovine semen quality. *Reprod. Domest. Anim*, 2011; 46: 66-73.
26. Sahin K, Ondereci M, Sahin N, Kucuk O, Dietary vitamin C and folic acid supplementation ameliorates detrimental effect of heat stress in Japanese quail, *J Nutr*, 133(6): 1882-1886.
27. Bandopadhyay, G, Sinha, S, Chattopadhyay, BD and Chakraborty, A. Role of curcumin against nicotine induced genotoxicity on rat liver under dietary protein. *European J. of Pharmacology*, 2008; 588: 151-157.