

## EFFECT OF RESVERATROL ON LIVER DIFFERENTIAL HEPATOCYTES AND KIDNEY HISTOPATHOLOGY ON LEAD-INDUCED TOXICITY IN WISTAR RATS

Salisu Muhammad Highab<sup>1\*</sup>, Rabiou Abdussalam Magaji<sup>2</sup>, Musa Aliyu<sup>3</sup>, Nuhu Muhammad Danjuma<sup>4</sup> and Bala Yauri Muhammad<sup>5</sup>

\*<sup>1</sup>Department of Physiology and Pharmacology, Faculty of Basic Medical Sciences, College of Medicine and Health Sciences, Federal University Dutse, Jigawa State, Nigeria.

<sup>2</sup>Department of Human Physiology, Faculty of Basic Medical Sciences, Ahmadu Bello University, Zaria, Kaduna State, Nigeria.

<sup>3</sup>Department of Pharmacology, Faculty of Pharmaceutical Sciences, Bayero University, Kano, Nigeria.

<sup>4</sup>Department of Pharmacology and Therapeutics, Faculty of Pharmaceutical Sciences, Ahmadu Bello University, Zaria 810001, Nigeria.

<sup>5</sup>Department of Pharmacology and Toxicology, Unaizah College of Pharmacy, Qassim University, Unaizah 51911, Al-Qassim Province, Saudi Arabia.

Article Received on  
03 June 2018,

Revised on 23 June 2018,  
Accepted on 14 July 2018,

DOI: 10.20959/wjpr201815-12923

### \*Corresponding Author

**Salisu Muhammad  
Highab**

Department of Physiology  
and Pharmacology, Faculty  
of Basic Medical Sciences,  
College of Medicine and  
Health Sciences, Federal  
University Dutse, Jigawa  
State, Nigeria.

### ABSTRACT

The aim of this experiment was to investigate the effect of resveratrol on liver differential hepatocytes and kidney histopathology in lead-induced toxicity in wistar rats. The study employed wistar rats (150 - 200 g) which were administered carboxymethylcellulose 10 g/l (control), lead acetate solution (120 mg/kg), lead acetate solution (120 mg/kg) and succimer (10 mg/kg BW); lead acetate solution (120 mg/kg) and resveratrol (200 mg/kg); lead acetate solution (120 mg/kg) and resveratrol (400 mg/kg); and resveratrol alone (400 mg/kg) then administered lead acetate solution (120 mg/kg) daily for 2 weeks and considered as prophylactic group. All treatments were through the oral routes by *gavage*. The organ samples were examined for histopathology. In the histopathology, the toxic effect of lead recorded in liver differential hepatocytes and kidney in the positive control

group were significant ( $p < 0.05$ ) when compared to resveratrol-treated

groups. The toxic effects caused by lead acetate were reduced to minimal level in resveratrol-treated groups. Resveratrol (200 mg/kg) treated rat's liver showed a marked improvement in the pattern of glycogen storage in hepatocytes. Resveratrol (400 mg/kg) treated rats' liver showed a marked improvement in the pattern of glycogen storage in hepatocytes more than as seen in resveratrol (200 mg/kg). Resveratrol pretreated rats' liver showed a marked improvement in the pattern of glycogen storage in hepatocytes more than as seen in resveratrol (400 mg/kg) treated rats. Rats treated with resveratrol (200 mg/kg) showed improved renal cortex histology, thus, no significant histopathology seen. Rats treated with resveratrol (400 mg/kg) showed well preserved renal cortex histology. Thus, no significant histopathology was seen. Rats pretreated with resveratrol (400 mg/kg) showed the same findings as that seen in resveratrol treated rats. In conclusion, resveratrol improved the adverse effects induced by the lead acetate in the liver differential hepatocytes and kidney tissues of the wistar rats.

**KEYWORD:** Resveratrol, Wistar Rats, Liver Differential Hepatocytes, Kidney, Lead Toxicity.

## 1.0 INTRODUCTION

The liver is the major organ of drug metabolism and is highly exposed to both indigenous and exogenous chemical substances. Studies have shown that the liver is one of the primary targets in lead associated toxicity. There are also reports from some quarters on lead induced liver damage which was mitigated by some chemical substances. In this section we critically examine literature on the mitigating effects of some chemical agents on lead associated liver damage. Researchers have shown that some extracts of plant and substances of animal origin have ameliorated lead impaired liver damage in experimental animal studies. Some synthetic chemical substances with known antioxidant properties were also reported to mitigate hepatotoxicity associated with lead. The hepatotoxicity of lead and the roles of mitigating chemical substances can be seen from the study performed by Koriem, 2009. He and colleagues administered 0.5 mg/g concentration of lead acetate to rats in diet for 60 days and observed significant increase in lipid peroxidation and transaminases while SOD, GPx and other biochemical parameters were decreased. These impaired biochemical parameters were normalized when 8 mg/100 g of rat body weight of methanol extract of *C. sempervirens*, 0.3 mg/100 g of quercetin and 0.1 mg/100 g of rat body weight of rutin were administered prior to lead acetate administration. Similar observation was reported by Waggas (2012), when he

injected rats (i.p.) with subacute dose (100 mg/kg body weight/day) of lead acetate and documented significant increase in serum glutamate oxaloacetate, transaminases, serum glutamate pyruvate transaminase and lactate dehydrogenase level. Pretreatment with Grape seed extract (*Vitisvinifera*) (100 mg/kg body weight/day) normalized these biochemical parameters. Liver enzymes were elevated while antioxidant enzymes were decreased and histopathological changes in the liver were noted when rats were exposed to lead acetate (0.2%) in drinking water for 4 weeks. Pretreatment with 1.5 ml/kg of natural honey orally for 4 weeks alleviated these lead induced changes (Halawa *et al.*, 2009). Aziz *et al.*, (2012) also reported the protective effect of 1:50 diluted latex/kg body weight of *Ficus latex* against 500 mg/L of lead acetate induced impairments of biomarkers of liver function and alterations in liver architecture of rats. Similar observation was reported by Falah, 2012 on the hepatoprotective effect of *Ficus carica L* in animal studies. The protective effect of the methanolic extract of *Pongamia pinnata* flowers was studied in rats with lead acetate induced hepatotoxicity.

The kidney is the major organ of drug excretion and is also one of the organs of primary target during lead toxicity. There are reports from some quarters on lead induced kidney damage in experimental animal studies and humans. Among reported studies on lead toxicity is the work of Missoun *et al.*, (2009) who exposed rats to 1000 ppm of lead acetate in drinking water for 8 weeks. He and friends documented increase in phosphaturia and calcium level. Decrease in level of creatinine, urea and presence of calcium oxalate dehydrate crystals observed in samples of urine of exposed rats was also reported. All lead treated rats showed intranuclear inclusion bodies in kidney proximal tubular. Some scholars also reported similar changes when they exposed animals to lead (Mohamed and Saleh, 2010). Deveci *et al.*, (2011) in a study to investigate the ultrastructural effects of lead on the kidney cortex of rats, exposed rats to drinking water containing 500 ppm lead acetate for a period of 2 months. Histopathological examination of the kidney revealed various degenerative changes with focal tubular necrosis invaded by inflammatory cells in cortical renal tubules. The ultrastructural alterations found in lead acetate treated rats were diminution in the amount of filtration slits, increased fusion of foot processes in epithelial cells of the glomeruli, increase in lysosomal structures and pinocytotic vesicles as well as large mitochondria in proximal tubule cells. Oral administration of lead acetate (10 mg/kg) to pregnant mice was reported to significantly decrease fetuses' cortical thickness. Moderate cortical tubular atrophy showing thickening of endothelial basement membrane in glomeruli, desquamated epithelium with

degenerated nuclei in proximal and distal tubules was observed in lead treated rats (Jabeen *et al.*, 2010). Ponce-Canchihuamán *et al.*, (2010) administered 25 mg/0.5 mL of lead acetate intraperitoneally to rats weekly. It was found that activities of SOD, CAT and GSH in rat kidney were significantly ( $p < 0.05$ ) decreased while level of MDA was significantly ( $p < 0.05$ ) increased with respect to the control. Berrahal and colleagues investigated the effects of chronic exposure to lead (50 mg/L) on kidneys of two different age groups of male rats from delivery until puberty period (40 days) and post puberty period (65 days). Results clearly showed that administration of lead produced oxidative damage in kidney, as strongly suggested by the significant increase in TBARS, decrease in total SH, the alteration of SOD activity and impairments of some kidney function parameters. This present research focus on investigating the effect of resveratrol on liver differential hepatocytes and kidney histopathology on lead-induced toxicity in wistar rats.

## 2.0 MATERIALS AND METHODS

### 2.1 MATERIALS

#### 2.1.1 Chemicals

*Trans*-resveratrol (60g) of analytical grade was obtained from Candlewood Stars Incorporated, Danbury, USA (Batch Number: MR 110218), while lead acetate (product No: 10142, BDH Laboratory Chemicals Limited Poole, England) and carboxymethylcellulose-CMC (10 g) (Product No: 27929, BDH Laboratory chemicals limited Poole, England) were obtained from the Department of Pharmacology and Therapeutics, Faculty of Pharmaceutical Sciences, Ahmadu Bello University, Zaria.

#### 2.1.2 Equipment

Some of the equipment's used in this study include Lead Care II User's Guide, Lead Care II blood analyser, Automated Haematology Analyzer (Sysmex model 2X-12N, USA). Automated Biochemistry Analyzer (Selectra XL, Vital Scientific, Netherlands) dissecting sets, syringes, and needles, spatula, reagent bottles, digital weighing balance, sensors (2 containers of 24 each), treatment reagent tubes, capillaries/plungers, transfer droppers, calibration button, alcohol wipes, gauze pads, power free gloves were used.

#### 2.1.3 Experimental Animals

Thirty six male wistar rats (150 - 250 g) were used in the study. The animals were housed in the Department of Pharmacology and Therapeutics, Ahmadu Bello University, Zaria. They were given access to pelletized growers marsh and water *ad libitum*. The rats were

acclimatized for two weeks in the home cages and environment before commencement of the experiment. All experimental protocols were in accordance with the Ahmadu Bello University research policy (NIH publication number 85-23, revised 1996) and of regulations governing the care and use of experimental animals. The experiments were conducted in a quiet environment between the hours of 0900 and 1600.

#### **2.1.4 Experimental Site**

The experiment was carried out between August- September, 2014 at the Department of Pharmacology and Therapeutics, Ahmadu Bello University, Zaria (11° 10' N, 07° 38' E), at the elevation of 650 m above sea level, located in the Northern Guinea Savannah zone of Nigeria (Akpa *et al.*, 2002).

### **2.2 METHODS**

#### **2.2.1 Experimental Procedures**

##### **2.2.1.1 Resveratrol Preparation and Administration**

*Trans*-resveratrol, due to its low solubility in water, was suspended in 10 g/L Carboxymethylcellulose (CMC), and administered orally once daily for 14 days (Lia *et al.*, 2002; Juan *et al.*, 2005).

##### **2.2.1.2 Lead Acetate Treatments and Resveratrol Pretreatment**

Wistar rats were divided into six groups of six rats each. The first group served as negative control and received carboxymethylcellulose (CMC) 10 g/L body weight orally. The second, third, fourth and fifth groups received lead acetate at dose of 120 mg/kg (Magaji *et al.*, 2014b) body weight orally for 14 days while the sixth group was pretreated with resveratrol 400 mg/kg body weight (Magaji *et al.*, 2014a, Joanne *et al.*, 2008) orally for 5 days and serve as prophylaxis.

##### **2.2.1.3 Treatments with Succimer and Resveratrol**

After the lead acetate induction for 14 days and resveratrol pretreatment for 5 days, the treatment commenced on the 15<sup>th</sup> day and lead acetate induction on the 5<sup>th</sup> day, where the second group positive control (lead poisoned), the third group was treated with succimer (10 mg/kg body weight) (POISINDEX, 2009; TOXBASE, 2009), the fourth group was treated with resveratrol (200 mg/kg body weight), the fifth group was treated with resveratrol (400 mg/kg body weight) orally for five (5) days and the sixth group was treated with lead acetate

at dose of 120 mg/kg body weight orally for 14 days and served as prophylactic group (Magaji *et al.*, 2014a; Joanne *et al.*, 2008).

### **2.2.2 Effect of Resveratrol on Histopathological Parameters in Lead-induced Toxicity in Wistar Rats**

After the animals were euthanized, vital organs including liver differential hepatocytes and kidney were removed from the rats and fixed in 10% formalin for at least 48 h, then processed routinely, and the tissues were embedded in paraffin wax. Histological sections were cut at 5 – 6  $\mu\text{m}$  and stained with routines Periodic Acid Schiff (PAS) and Haematoxylin and Eosin (H & E) (Bancroft and Stevens, 1996). Detailed microscopic examinations were carried out by a consultant histopathologist. Photomicrographs of the organs were taken at various magnifications ( $\times 100$ ,  $\times 250$ , and  $\times 400$ ).

## **3.0 RESULTS**

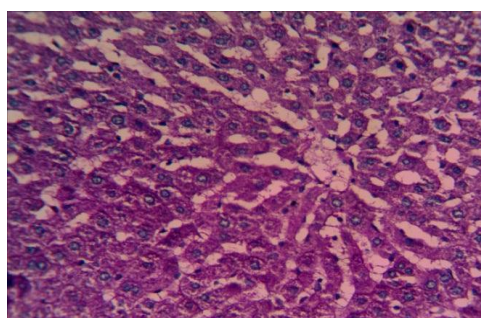
### **3.1 Effect of Resveratrol on Liver Differential Hepatocyte Histopathology in Lead-induced Toxicity in Wistar Rats**

The periodic acid schiff (PAS) stain result of the liver showed normal storage of glycogen deposit in hepatocytes (magenta colour) in carboxymethylcellulose treated rats (Plate 3.1 (1)). Lead acetate treated rat's liver showed a distortion in the pattern of glycogen storage in hepatocytes with diminished glycogen deposit (Plate 3.1 (2)). Succimer treated rat's liver showed slight improvement in the pattern of glycogen storage in hepatocytes with reduced glycogen deposit (Plate 3.1 (3)). Resveratrol (200 mg/kg) treated rat's liver showed a marked improvement in the pattern of glycogen storage in hepatocytes (Plate 3.1 (4)). Resveratrol (400 mg/kg) treated rats' liver showed a marked improvement in the pattern of glycogen storage in hepatocytes more than as seen in resveratrol (200 mg/kg) (Plate 3.1 (5)). Resveratrol pretreated rats' liver showed a marked improvement in the pattern of glycogen storage in hepatocytes more than as seen in resveratrol (400 mg/kg) treated rats (Plate 3.1 (6)). Distilled water treated rats liver showed normal storage of glycogen deposit in hepatocyte (Plate 3.1 (7)).

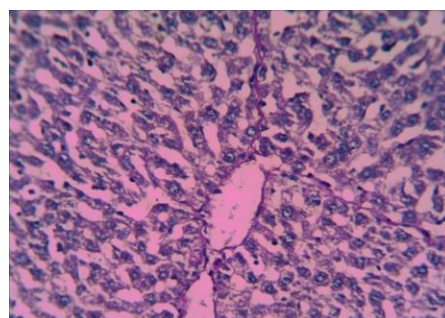
### **3.2 Effect of Resveratrol on Kidney Histopathology in Lead-induced Toxicity in Wistar Rats**

Kidney renal cortex of the carboxymethylcellulose treated rat's revealed normal histology of the renal cortex (Plate 3.2 (1)). Rats treated with lead acetate only showed a significant infiltration by macrophages (Plate 3.2 (2)). Rats treated with succimer showed an improved

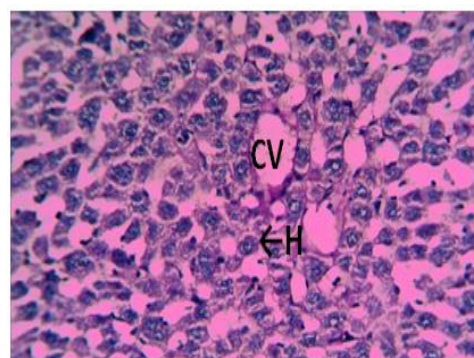
architecture of the renal cortex, however, there was slight infiltration by macrophages (Plate 3.2 (3)). Rats treated with resveratrol (200 mg/kg) showed improved renal cortex histology, thus, no significant histopathology seen (Plate 3.2 (4)). Rats treated with resveratrol (400 mg/kg) showed well preserved renal cortex histology. Thus, no significant histopathology was seen (Plate 3.2 (5)). Rats pretreated with resveratrol (400 mg/kg) showed the same findings as that seen in resveratrol treated rats (Plate 4.4 (6)). Distilled water treated rats showed normal renal cortex of the kidney (Plate 3.2 (7)).



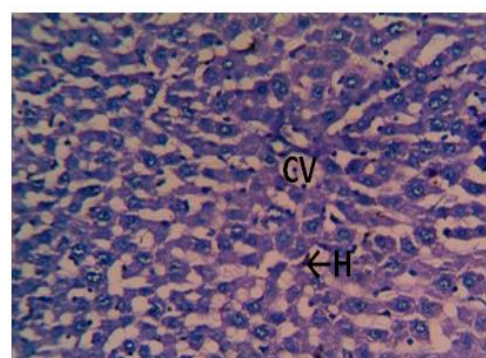
1



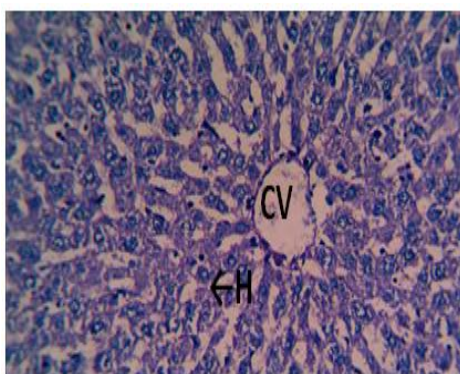
2



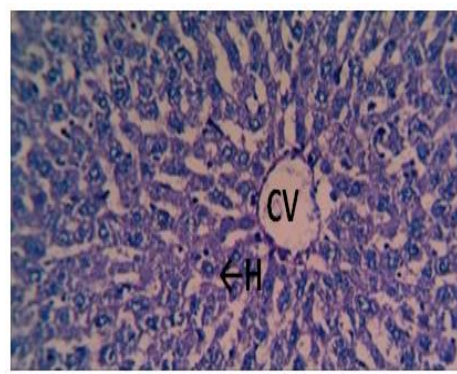
3



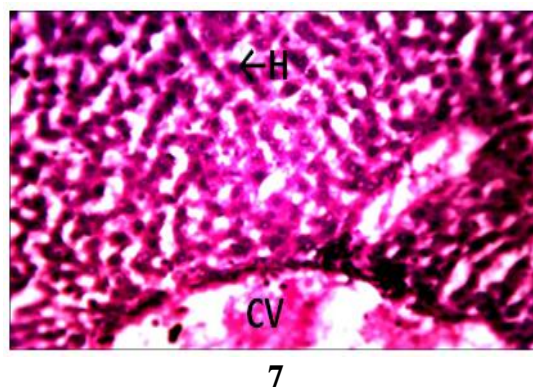
4



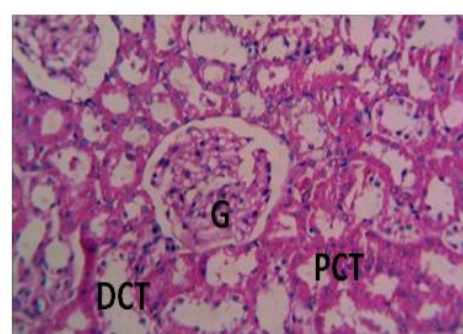
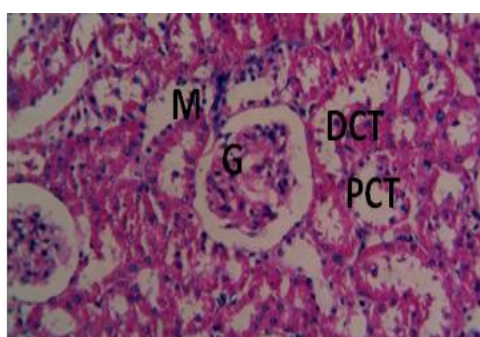
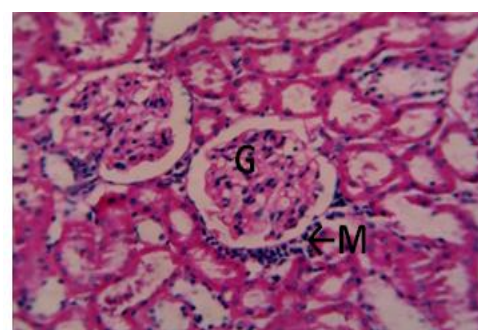
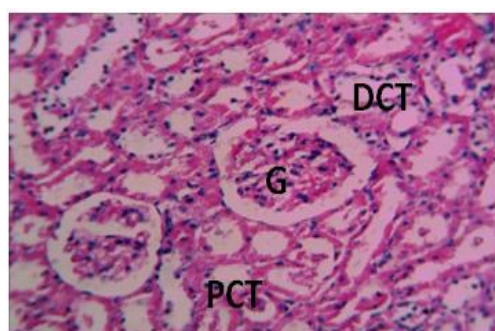
5



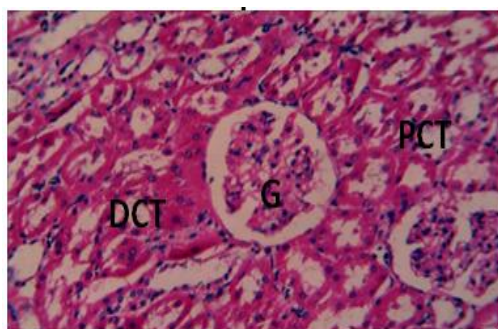
6



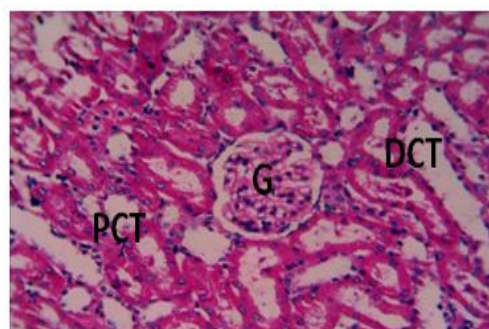
**PLATE 3.1** Photomicrograph of liver from (1) Rats treated with carboxyl methylcellulose (10g/L). Note, hepatocyte (H) with glycogen deposit (magenta colour) (arrow); central vein (CV), (2) Rats treated with lead acetate (120 mg/kg). Note –hepatocyte (H) with diminished glycogen deposit (arrow); CV-central vein, (3) rat treated with succimer (10mg/kg). Note – hepatocyte (H) with reduced glycogen deposit (arrow); CV-central vein, (4) Rats treated with resveratrol (200 mg/kg). Note –hepatocyte (H) (arrow); central vein (CV), (5) Rats treated with resveratrol (400 mg/kg). Note –hepatocyte (H) (arrow); CV-central vein, (6) Rats treated with resveratrol (400 mg/kg) and lead acetate (120 mg/kg). Note –hepatocyte (H) (arrow); CV-central vein. (7) Rats treated with distilled water Note, hepatocyte (H) with glycogen deposit (magenta colour) (arrow); central vein (CV). PAS x 250.



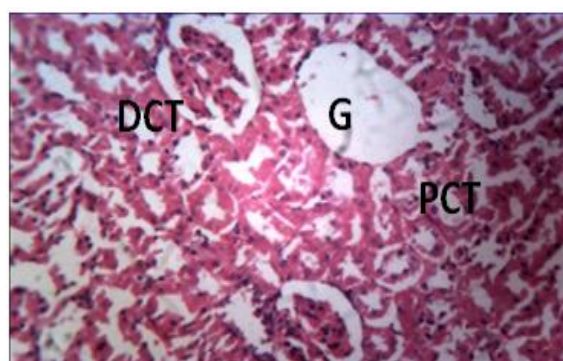




5



6



7

#### 4.0 DISCUSSION

The periodic acid schiff (PAS) stain result of the liver revealed normal storage of glycogen deposit in hepatocytes (magenta colour) in carboxymethylcellulose treated rats. Lead acetate treated rats liver revealed a distortion in the pattern of glycogen storage in hepatocytes with diminished glycogen deposit which may be as a result of the effect of the lead acetate administered. The administration of succimer and resveratrol revealed improvement in the pattern of glycogen storage in succimer, resveratrol treated and resveratrol pretreated rats. This may be as a result of reduced intoxication of lead acetate in those groups or may be as a result of chelating properties of succimer and resveratrol.

Examination of the kidney of animals treated with carboxymethylcellulose showed normal histological architecture of kidney cortex with clear glomerulus, proximal convoluted tubule, and distal convoluted tubule. Lead acetate treated wistar rats revealed focal replacement of renal parenchyma by lymphocytes, macrophages and coagulative necrosis. Similar histopathological lesions have been reported in experimental lead acetate toxicity with different species by Durgut *et al.*, (2008), Rader *et al.*, (1983) and Vyskocil *et al.*, (1995). Lead acetate treated wistar rats also revealed intranuclear inclusion bodies in kidney proximal tubules. Some scholars also reported similar changes when they exposed animals to lead

(Mohamed and Saleh, 2010). Furthermore, resveratrol treated animals happened to have corrected most of the destructions made by lead acetate by improving the architecture of the kidney looking almost similar to that of the negative control group. This study also revealed that, the effectiveness of resveratrol is dose dependent because rats treated and pretreated with resveratrol 400 mg/kg showed more improvement by restoring the normal architecture of the kidney as seen in the negative control group. Similar findings were reported by Ashour *et al.*, (2007).

#### 4.1 CONCLUSION

In conclusion, resveratrol reduced the adverse effect induced by lead on the liver differential hepatocytes and kidneys.

#### ETHICAL APPROVAL

All authors hereby declare that "Principles of laboratory animal care" (NIH publication No.85- 23, revised 1985) were followed, as well as specific national laws where applicable. All experiments have been examined and approved by the appropriate ethics committee.

#### COMPETING INTERESTS

Authors have declared that no competing interests exist.

#### REFERENCES

1. Akpa, G.N., Asiribo, O.O., Alawa, J.P., Dim, N.I., Osinowo, O.A. and Abubakar, B.Y. Milk production by agropastoral Red Sokoto goats in Nigeria. *Tropical Animal Production*, 2002; 34: 526 – 533.
2. Ashour, A.A., M.M. Yassin, N.M. Abu Aasi and R.M. Ali, Blood, serum glucose and renal parameters in lead-loaded albino rats and treatment with some chelating agents and natural oils. *Turkey Journal of Biology*. 2007; 31: 25-34.
3. Aziz, F.M., I. M.Maulood and M.A.H. Chawsheen, Effects of melatonin, vitamin C and E alone or in combination on lead-induced injury in liver and kidney organs of rats. *IOSR J. Pharmacy*, 2012; 2(5): 13-18.
4. Bancroft, J.D., Gamble, M., Theory and Practice of Histological Techniques. 6<sup>th</sup> ed. New York/London: Churchill Livingstone; 2008; 165-175.
5. Deveci, E., S. Söker, O. Baran, S. Tunik and E. Ayaz, Ultrastructural changes in the kidney cortex of rats treated with lead acetate. *Int. J. Morphol.*, 2011; 29(3): 1058-1061.

6. Durgut R, Koc A, Gonenci R, Bal R, Celik S, Guzel M, Altug M, Atesoglu E. Effects of high dose lead toxication on liver, kidneys, heart, brain and blood in rabbits: an experimental study. *Journal of Applied Biology Science*; 2008; 2: 11-18.
7. Falah, A.M., Protective effects of latex of *Ficus carica* L. against lead acetate-induced hepatotoxicity in rats. *J. J. Biol. Sci.*, 2012; 5(3): 175.
8. Halawa, H.M., N.E. El-Nefiawy, N.A. Makhoulf and A.M. Awatef, Evaluation of honey protective effect on lead induced oxidative stress in rats. *JASMR*, 2009; 4(2): 197-209.
9. Jabeen, R., M. Tahir and S. Waqas, Teratogenic effects of lead acetate on kidney. *J. Ayub Med. Coll. Abbottabad*, 2010; 22(1): 76-79.
10. Joanne M.A, Xiaomei L, Christopher Q.R, Brandi P, and MinYou Resveratrol alleviates alcoholic fatty liver in mice. *American Journal of Physiology. Gastrointestinal and Liver physiology*: 2008; 295(4): G833-G842.
11. Juan, M.E., González-Pons, E., Munuera, T., Ballester, J., Rodríguez-Gil, J.E. and Planas, J.M. *Trans*-resveratrol, a natural antioxidant from grapes, increases sperm output in healthy rats. *Journal of Nutrition*, 2005; 135: 757-760.
12. Koriem, K.M., Lead toxicity and the protective role of *Cupressus sempervirens* seeds growing in Egypt. *Rev. Latinoamer. Quím.*, 2009; 37(3): 230-242.
13. Lia M. E., Juan, M. Pilar Vinardell, and J. M. Planas, "The daily oral administration of high doses of *trans*-resveratrol to rats for 28 days is not harmful," *Journal of Nutrition*, 2002; 132(2): 257-260.
14. Magaji G.M, Abolarin M, Opeyemi I.A, Magaji A.R, Modulatory Effect of Resveratrol on Neuropsychiatric Behavior in Mice. Department of Pharmacology and Therapeutics, Ahamdu Bello University, Zaria Nigeria. Conference abstract., 2014a.
15. Magaji, R.A; Magaji, M.G; Yusha'u, Y; Faruk, F; Muhammad, U.A and Fatihu, M.Y., Book of proceedings of the world congress of pharmacology,. *Final abstract* No. 1158, 2014b; 65.
16. Missoun, F., M. Slimani and A. Aoues, Toxic effect of lead on kidney function in rat Wistar African. *J. Biochem. Res.*, 2009; 4(2): 21-27.
17. Mohamed, N.A. and S.M. Saleh, Effect of pre and postnatal exposure to lead acetate on the kidney of male albino rat: A light and electron microscopic study. *Egypt. J. Histol.*, 2010; 33(2): 365-379.

18. POISINDEX Succimer. In Klasco RK (Ed): POISINDEX® System. Thomson Micromedex, Greenwood Village, Colorado, USA. Accessed at <http://www.thomsonhc.com> 7 April 2009).
19. Ponce-Canchihuamán, J.C., O. Pérez-Méndez, R. Hernández-Muñoz and P.V. Torres-Durán, Protective effects of *Spirulina maxima* on hyperlipidemia and oxidative-stress induced by lead acetate in the liver and kidney. *Lipids Health Dis.*, 2010; 9: 35.
20. Rader JL, Celesk EM, Peeler JR, Mahaffey KR. Retention of lead acetate in weaning and adult rats. *Toxicol Appl Pharmacol.*; 1983; 67: 100-109.
21. TOXBASE, Lead chelation therapy in children. United Kingdom National Poisons Information Service. Accessed at [www.toxbase.org](http://www.toxbase.org), 17 August 2009.
22. Vyskocil A, Semecky V, Fiala Z Cizkova M, Viau C. Renal alterations in female rats following subchronic lead exposure. *Journal of Applied Toxicology*; 1995; 15: 257–262.
23. Waggas, A.M., Grape seed extract (*Vitisvinifera*) alleviate neurotoxicity and hepatotoxicity induced by lead acetate in male albino rats. *J. Behav. Brain Sci.*, 2012; 2: 176-184.