

ODONTOGENIC KERATOCYST- A CASE REPORT**Dr. Mathew O. Mampilly***

Assistant Professor, Dept. of Dentistry, Esic Medical College and Post Graduate Institute
Rajajinagar, Bangalore.

Article Received on
03 Jan. 2020,

Revised on 23 Jan. 2020,
Accepted on 13 Feb. 2020

DOI: 10.20959/wjpr20203-16911

Corresponding Author*Dr. Mathew O. Mampilly**

Assistant Professor, Dept. of
Dentistry, ESIC Medical
College and Post Graduate
Institute Rajajinagar,
Bangalore.

ABSTRACT

Odontogenic keratocyst has been renamed as Keratocystic odontogenic tumor by world health organization in 2005. However it is now renamed back as Odontogenic keratocyst by Who in latest classification. It is a benign intraosseous neoplasm of the jaw. They develop from the dental lamina remnants in the mandible and maxilla. Odontogenic keratocyst is of particular interest because of its recurrence rate and aggressive behaviour. We present a case in a middle aged male patient.

KEYWORDS: Odontogenic keratocyst, Intraosseous, Keratocystic odontogenic tumor.

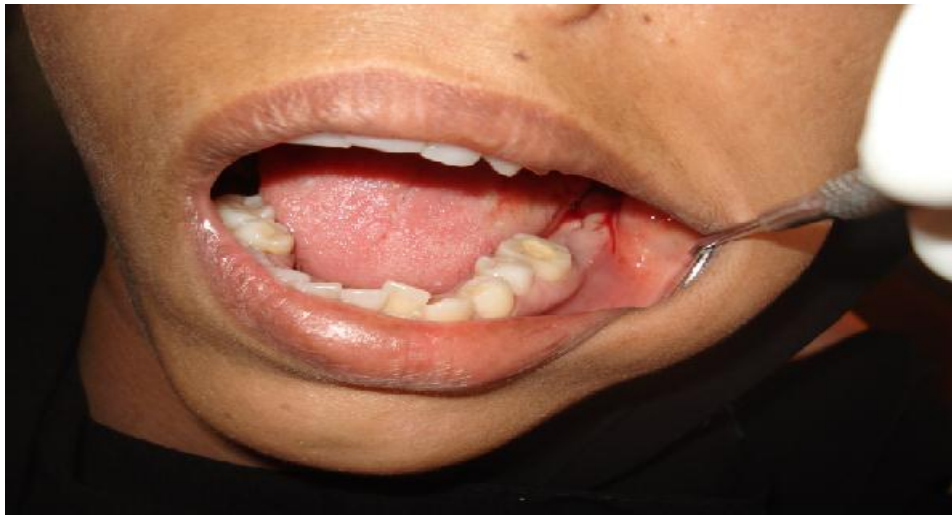INTRODUCTION

Odontogenic keratocyst (OKC) is a benign odontogenic cyst with aggressive behavior and a high recurrence rate.^[1,2] In the 2005 edition of the World Health Organization Classification of the Head and Neck Tumors, the odontogenic keratocyst was reclassified from a cystic to a neoplastic lesion, and the term “keratocystic odontogenic tumor” (KCOT) was coined.^[3] In the recent World Health Organization classification of tumours of the head and neck,^[1] the name keratocystic odontogenic tumour (KCOT) has been changed again to odontogenic keratocyst (OKC).^[4]

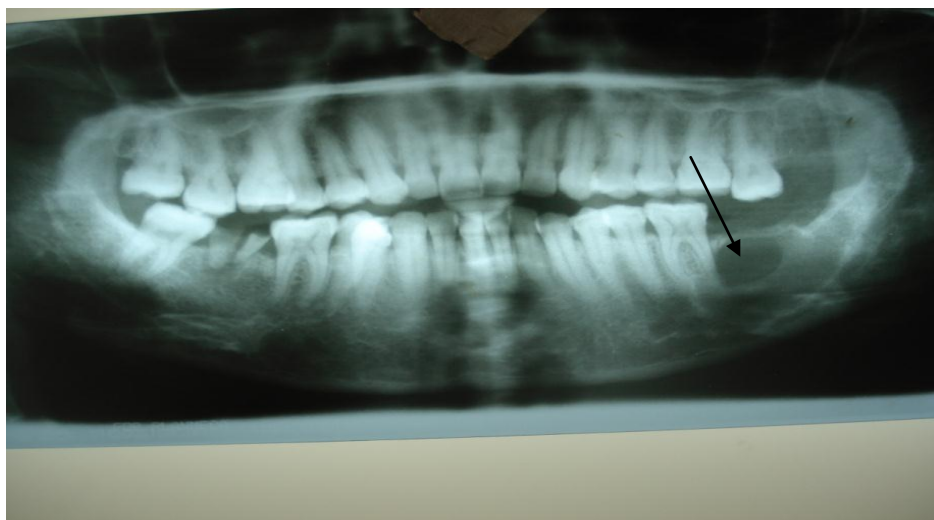
The OKC contributes approximately 11% of cysts of the jaws & is most commonly located in the mandibular ramus & angle. Most common site is the mandibular third molar region. Remnants of odontogenic epithelium persists in oral tissues after odontogenesis is complete and a variety of tumor and cysts may arise from these remnants.^[5]

CASE REPORT

A 21 year old male patient came to the dental clinic complaining of pain and swelling in relation to left lower posterior region. Pain was localized and dull in nature. There was facial asymmetry and evidence of swelling over the cheek extra orally (Fig 1). The patient underwent an extraction of 38 and 37. But the pain persisted and there was also a discharge from the extracted site.

**Fig: 1**

On intra oral examination an unhealed socket in relation to 37 was seen and there was tenderness on palpation. Ortho pantamograph revealed a radiolucency in relation to the 37, 38 region (Fig: 2). The lower border was intact and there was no evidence of any bone expansion.

**Fig: 2**

OPG revealing radiolucency in relation to 37 and 38 region.

An Excisional biopsy was performed and 3x1.5cm in size, firm in consistency was obtained. According to histopathological examination lesion was diagnosed as odontogenic keratocyst. Microscopic features of excised tissue showed odontogenic epithelial lining and connective tissue wall. The cyst is lined by parakeratinized stratified squamous epithelium which is about 4-6 layers thick without rete ridges (Fig: 3). The parakeratotic layer has corrugated surface (Fig: 4) and there is evidence of columnar palisaded basal cell layer.

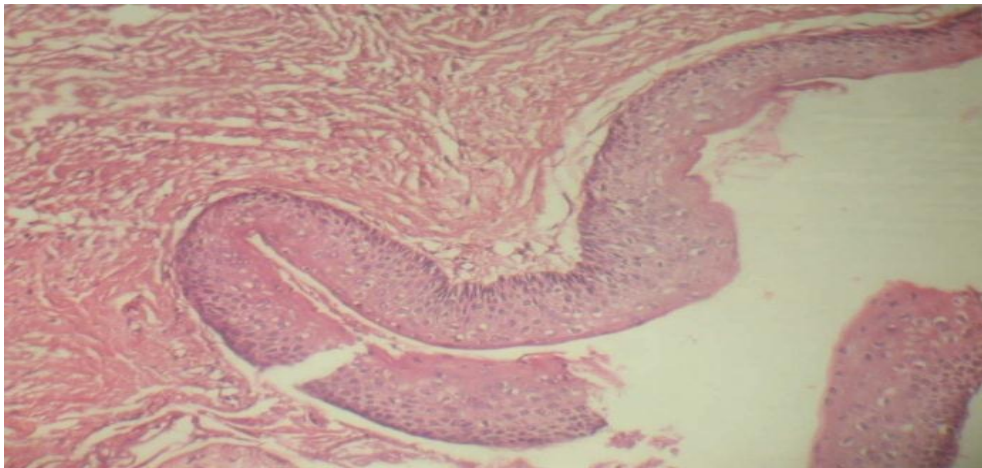


Fig: 3

H & E stained section in lower magnification showing parakeratinized stratified squamous epithelium which is about 4-6 layers thick without rete ridges.

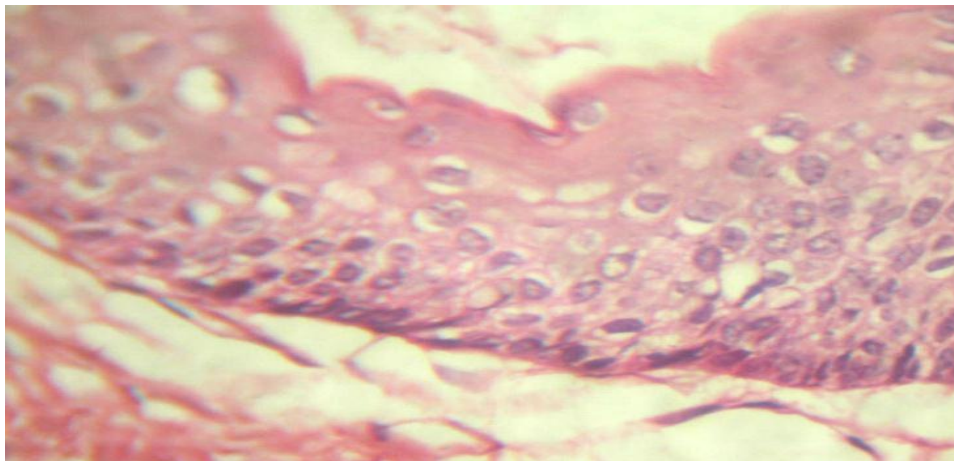


Fig: 4

H & E stained section in higher magnification showing corrugated surface in the parakeratotic layer.

DISCUSSION

The term Odontogenic Keratocyst was introduced by Philipsen in 1956. Keratocystic odontogenic tumor is believed to be a developmental cyst which originates from the dental lamina or its remnants.^[6] The first description of a solid variant of KCOT was reported by Ide Ide et al in 2003.^[7] KCOT is more common in males than females and occurs over a wide age range and is diagnosed during second to fourth decade.^[8,9] OKC has a predilection for occurring in the mandible as compared to maxilla.^[1] OKC has extension through the bone much more than bone expansion, thus until tumor does not reach its significant dimensions ,expansion is less important.^[10] OKC is difficult to diagnose clinically due to lack of specific clinical and radiographic characteristics.^[6] Radiographically OKC presents as a unilocular or a multilocular radiolucency with scalloped and well defined margins.^[11]

Histologically OKC shows an epithelial lining consisting of a uniform layer of stratified squamous epithelium usually six to eight cells in thickness. Cystic lumen may contain a clear liquid or it may be filled with a cheesy substance that consists of keratinaceous debris. Basal epithelial layer consists in a palisaded layer of cuboidal or columnar epithelial cells, which are often hyperchromatic. Small daughter cysts, cords or islands of odontogenic epithelium may be observed within fibrous wall.^[12] The treatment options for keratocystic odontogenic tumors varies from simple curettage, enucleation (in combination with cryotherapy or Carnoy`s solution), marsupialization, decompression and secondary enucleation, and resection (marginal or segmental).^[13,14] Decompression and marsupialization are the most common used procedures in cases of a large mandibular and maxillary tumors, because they can save the anatomical structures including adjacent teeth, maxillary sinus or inferior alveolar nerve.^[15,16]

CONCLUSION

Okcs are typically identified in routine radiographic examinations because of their biologic behavior, and they may be small initially. OKC has been the subject of much debate with respect to its origin, its growth, and treatment modalities. They are known for their peculiar behaviour, varied origin, unique tendency to recur. Post operative follow up is essential following surgical management due to its high recurrence.

REFERENCES

1. Godhi SS, Kukreja P. Keratocystic odontogenic tumor: A review. *J Maxillofac Oral Surg.*, 2009; 8: 127-31.
2. Maurette PE, Jorge J, de Moraes M. Conservative treatment protocol of odontogenic keratocyst: A preliminary study. *J Oral Maxillofac Surg.*, 2006; 64: 379-83.
3. Philipsen HP: Keratocystic odontogenic tumor, in Barnes L, Everson JW, Reichart P, Sidransky D (eds): *World Health Organization Classification of Tumors: Pathology and Genetics of Head and Neck Tumors*. Lyon, IARC Publishing Group, 2005; 306.
4. Stoelinga PJ. Long term follow up on keratocysts treated according to a defined Protocol *IJOMS*, 2001; 30: 14.
5. Speight, P., Devilliers, P., Li, T.J., Odell, E.W., Wright, J.M. Odontogenic keratocyst. in: A.K. El-Naggar, J.K. Chan, J.R. Grandis, T. Takata, P.J. Slootweg (Eds.) *World Health Organization classification of head and neck tumours*. Fourth edition. IARC, Lyon, 2017; 235–236.
6. O. Ribeiro-Júnior, A. M. Borba, C. A. F. Alves, M. M. d. Gouveia, M. C. Z. Deboni, and M. d. G. Naclério-Homem, “Reclassification and treatment of odontogenic keratocysts: a cohort study,” *Brazilian Oral Research*, 2017; 31: 98.
7. Philipsen. H. P On keratocysts in the jaws. *Tandlegebladet.*, 1956; 60: 963.
8. Ide F, Mishima K, Saito I: Solid-cystic variant of odontogenic keratocyst: An aggressive but benign lesion simulating keratoameloblastoma. *Virchows Arch.*, 2003; 442: 501.
9. D. MacDonald, “Lesions of the jaws presenting as radiolucencies on cone-beam CT,” *linical. Radiology*, 2016; 7110: 972–985.
10. Brad W Neville, Damm Douglas D, Carl M Allen, Jerry E Bouquot. *Odontogenic cysts and Tumors. Oral and Maxillofacial Pathology*, Noida, Saunders (Elsevier) Publications., 2009; 3: 683-87.
11. Giuliani M, Grossi GB, Lajolo C, Bisceglia M, Herb KE. Conservative management of a large odontogenic cyst: report of a case and review of literature. *J. Oral Maxillofac Surg.*, 2006; 64: 308-316.
12. Shear M, Speight P. *Cysts of oral and maxillofacial regions* (4th edition). Oxford Blackwell Munksgaard., 2007; 6-58.
13. Çakur B, Miloğlu Ö, Yolcu Ü, Göregen M, Gürsan N. Keratocystic odontogenic tumor invading the right maxillary sinus: a case report. *J Oral Sci.*, 2008; 50(3); 345-349.
14. Ortakoğlu K, Sürer BT, Şençimen M. A large keratocyst containing a third molar tooth in the maxillary antrum. *Turk J Med Sci.*, 2005; 35: 341-346.

15. Ç. Karaca, K. A. Dere, N. Er et al., “Recurrence rate of odontogenic keratocyst treated by enucleation and peripheral ostectomy retrospective case series with up to 12 years offollow-up,” *Medicina Oral Patología Oral y Cirugia Bucal*, 2018; 23: e443–e448.
16. Jung YS, Lee SH, Park HS. Decompression of large odontogenic keratocysts of the mandible. *J Oral Maxillofac Surg.*, 2005; 63(2): 267-271.